

**It is not that what it looks-like**

**Abbas Agaimy  
Universität Erlangen**



# Messages delivered by these illustrative cases

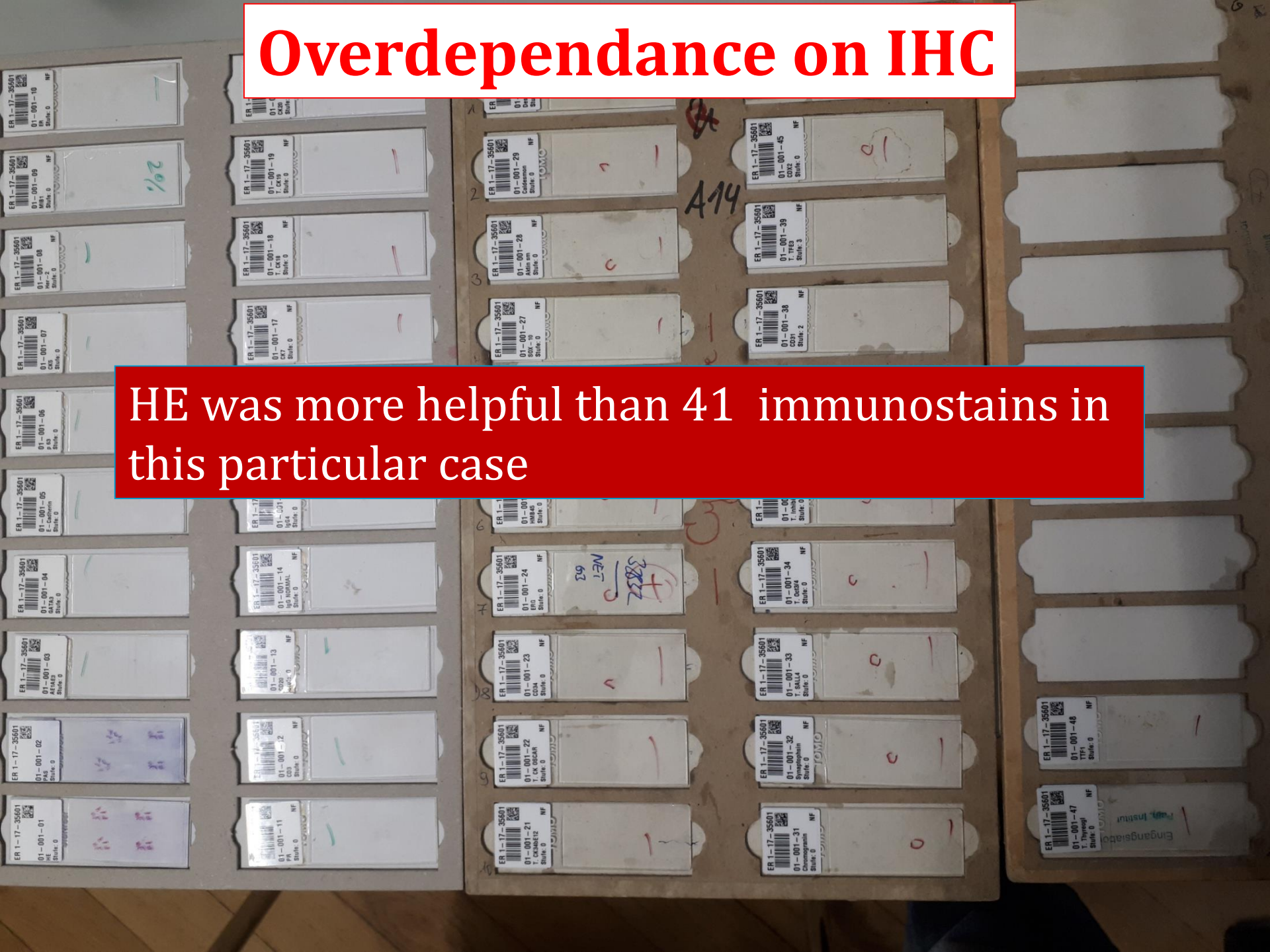
- **Avoid overdependance on IHC**
- **Recognize histological & immuno-mimicry**
- **Consider new entities & variants**
- **Interpret immuno & molecular in clinicopathological context.**
- **Expect (do not miss) the unexpected.**





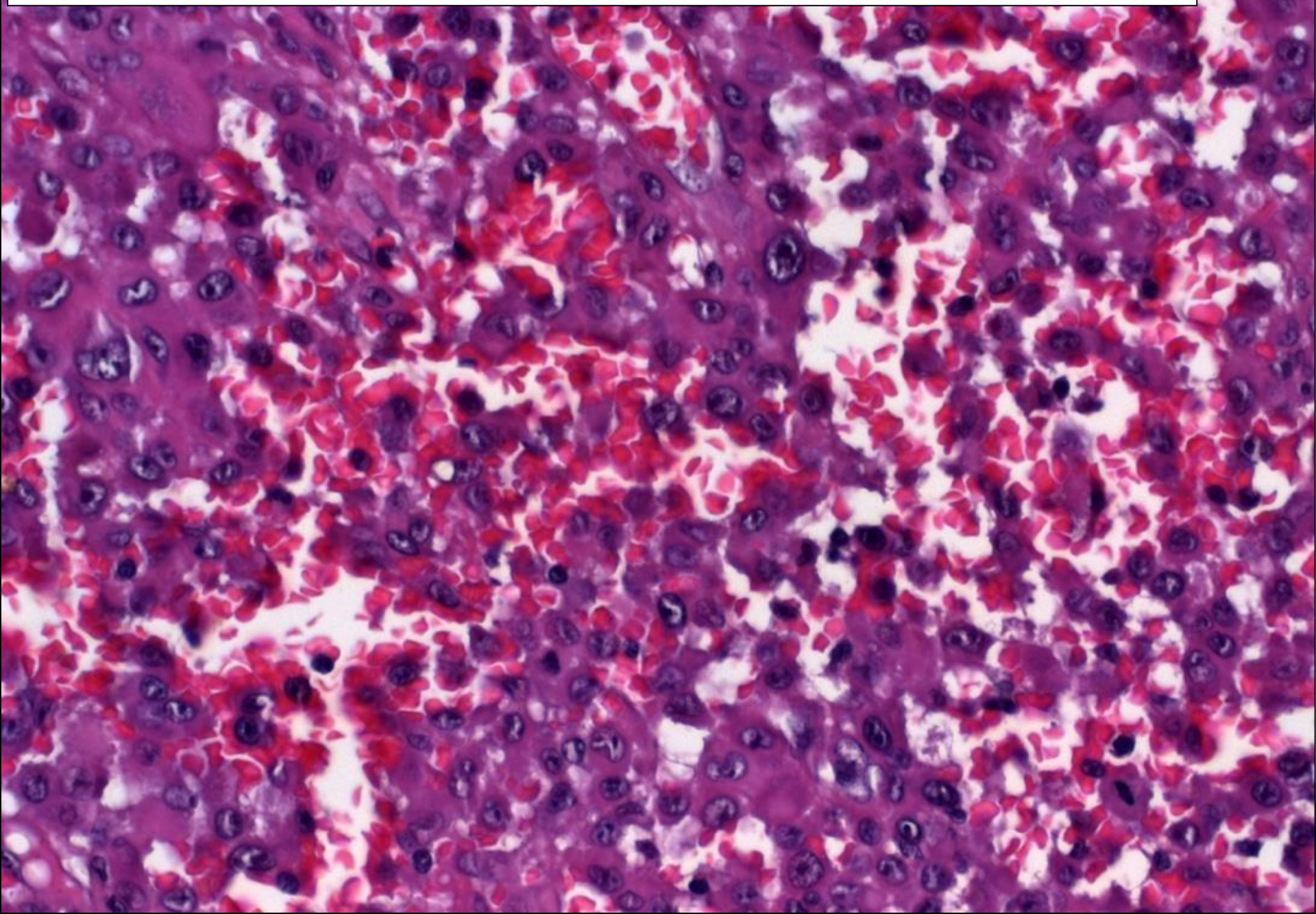
# Overdependance on IHC

HE was more helpful than 41 immunostains in this particular case



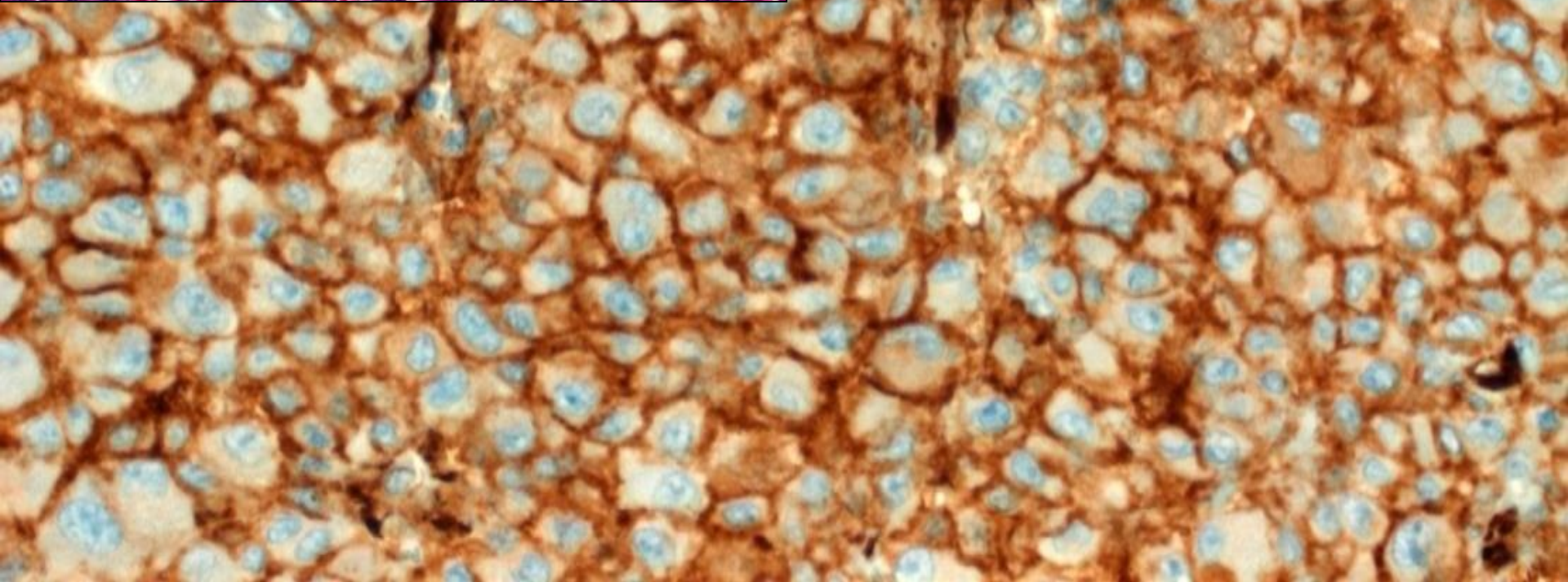
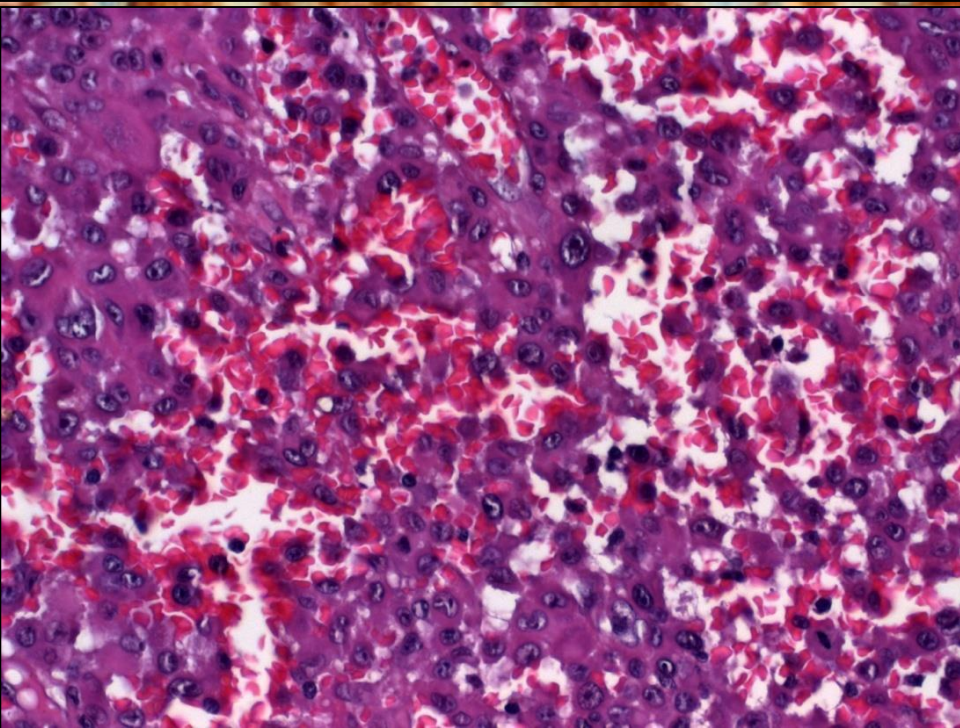


**65 yo male, ulcerated bleeding skin tumor, forehead**

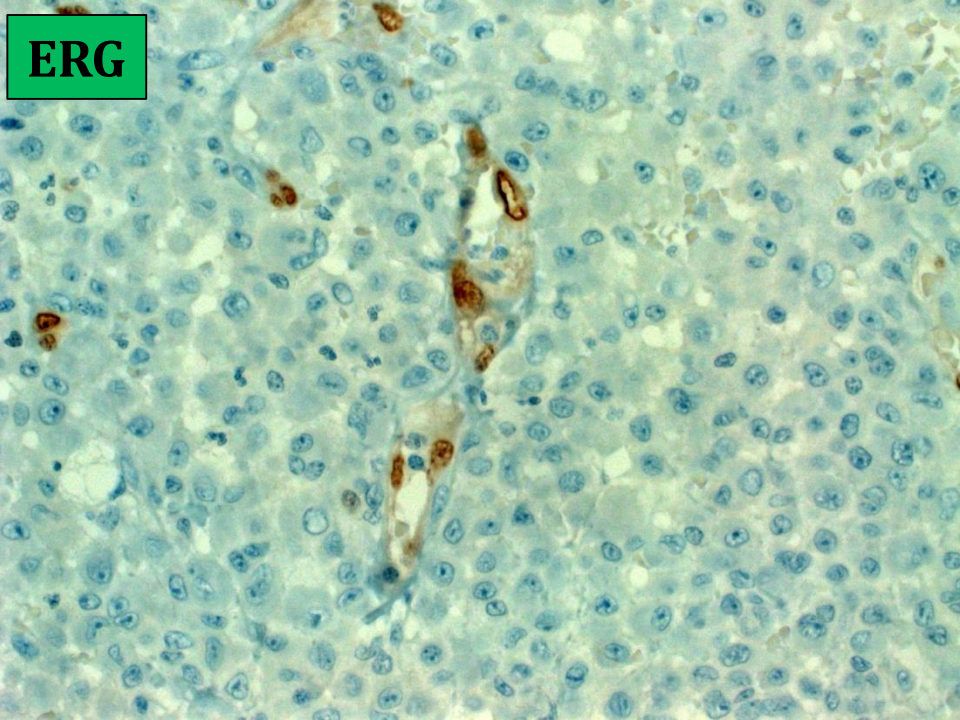
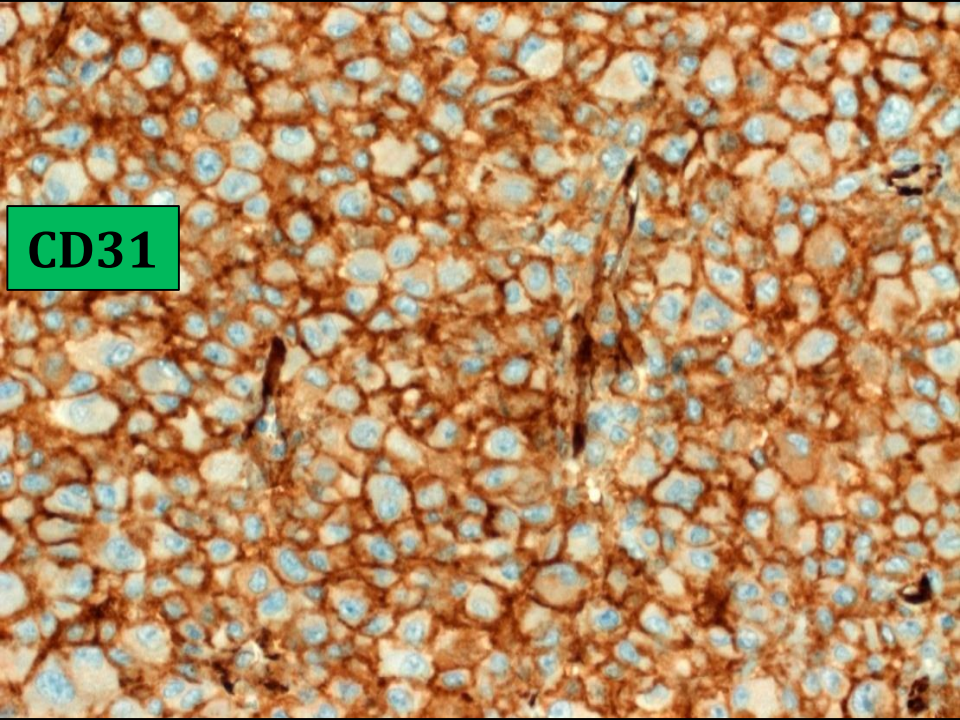
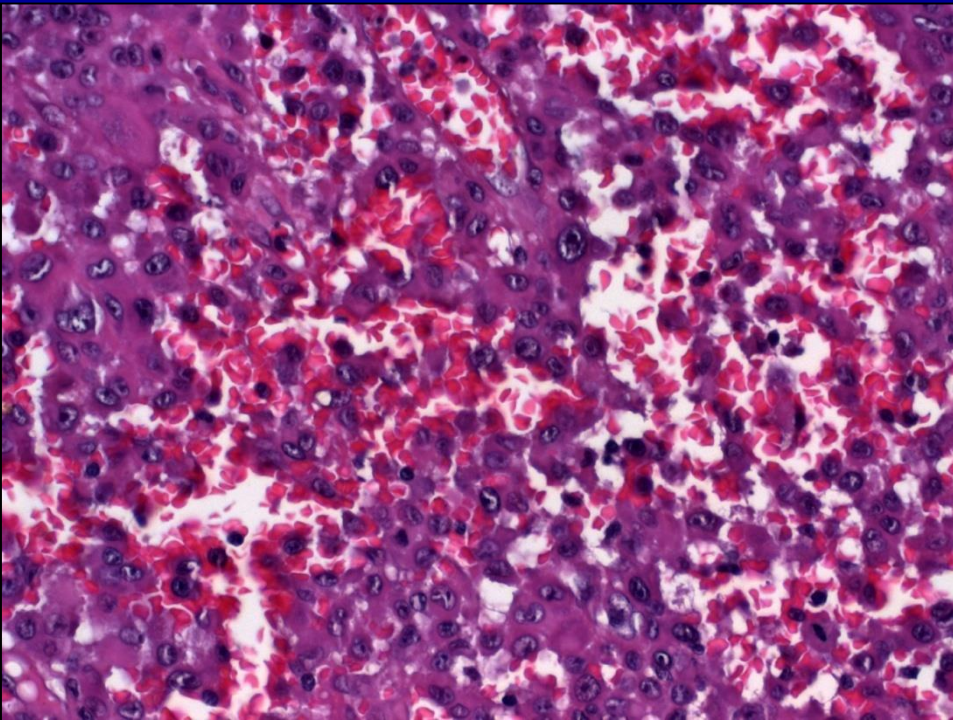




CD31



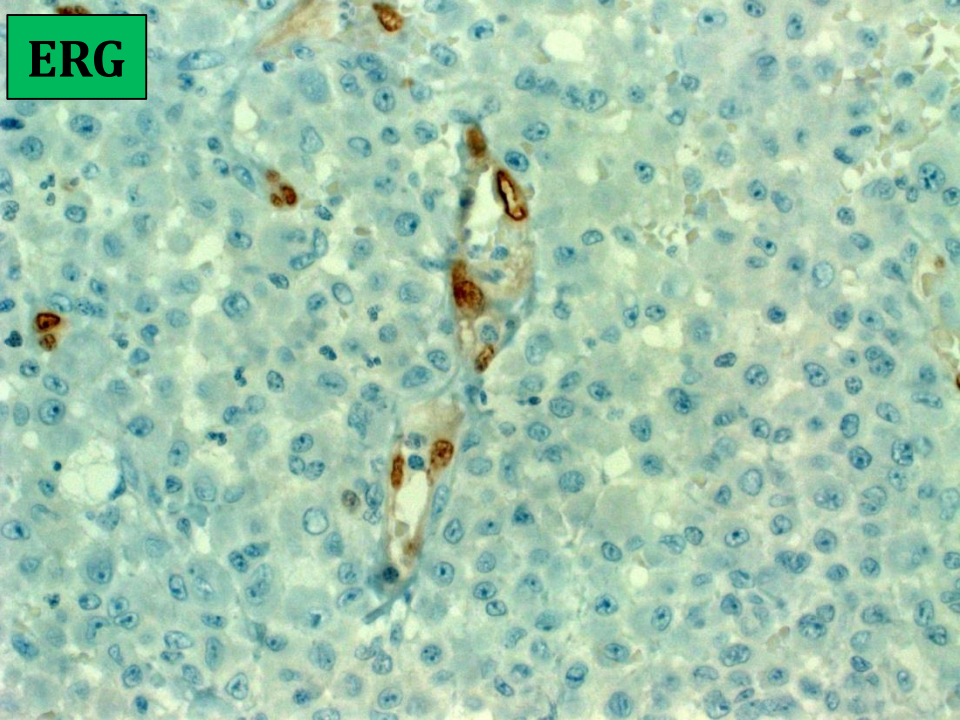
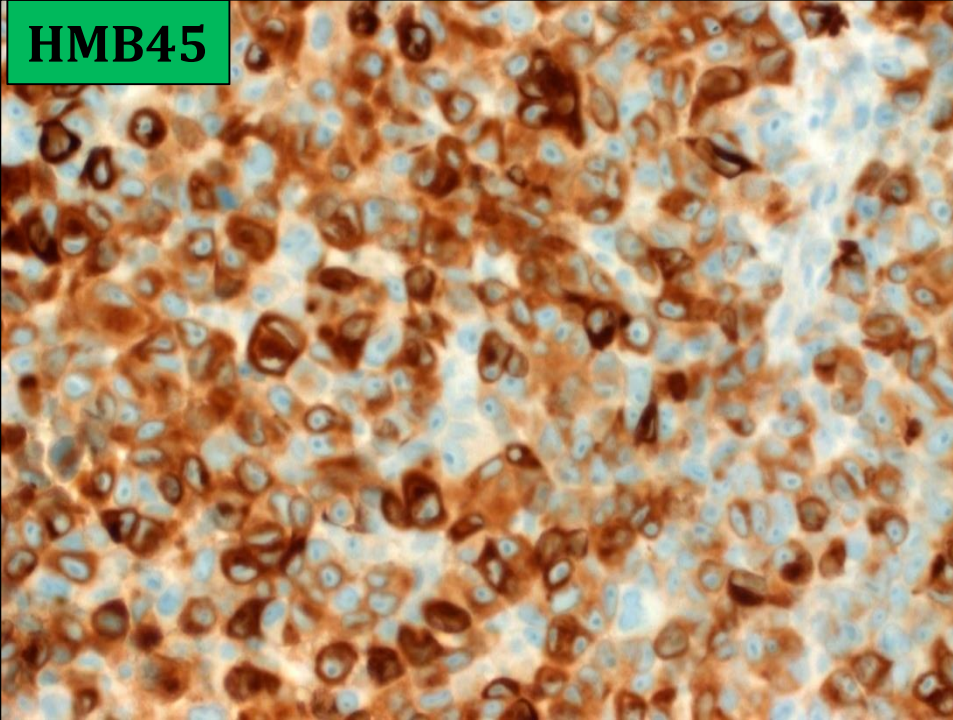
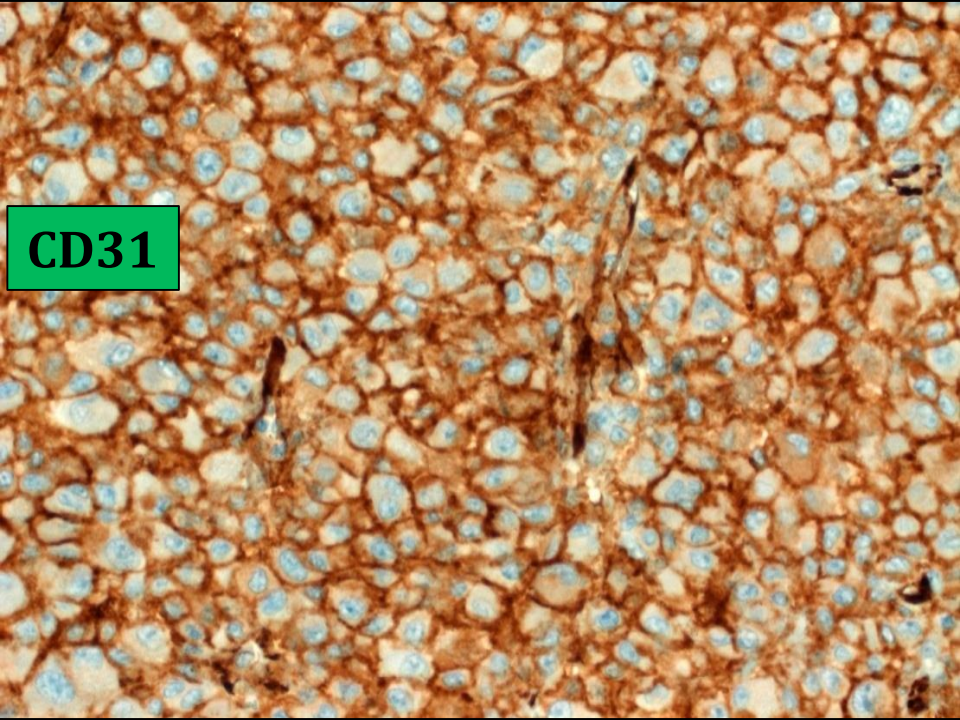
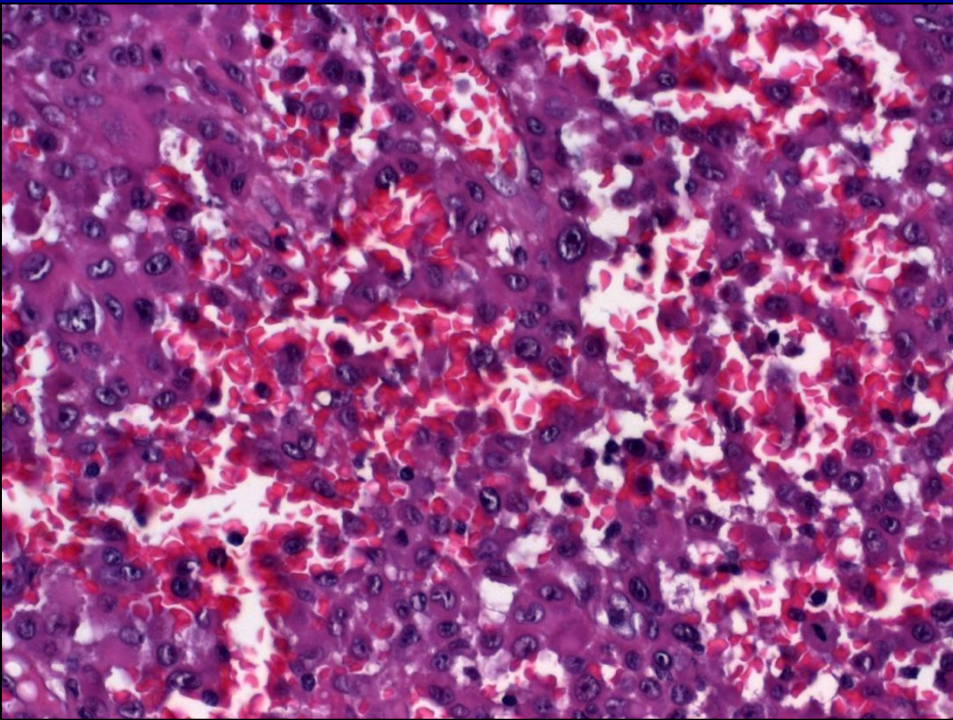




**CD31**

**ERG**





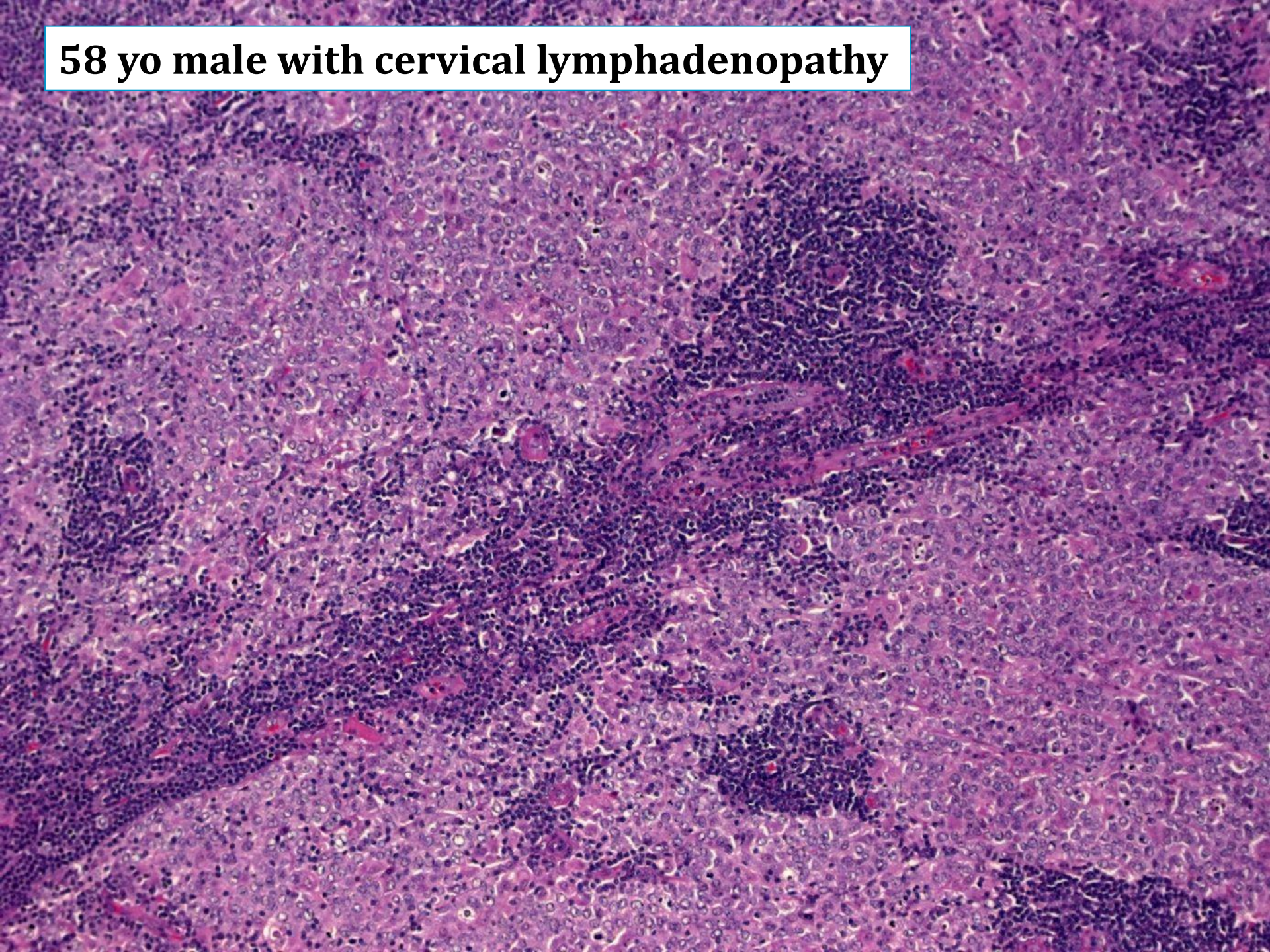
**CD31**

**HMB45**

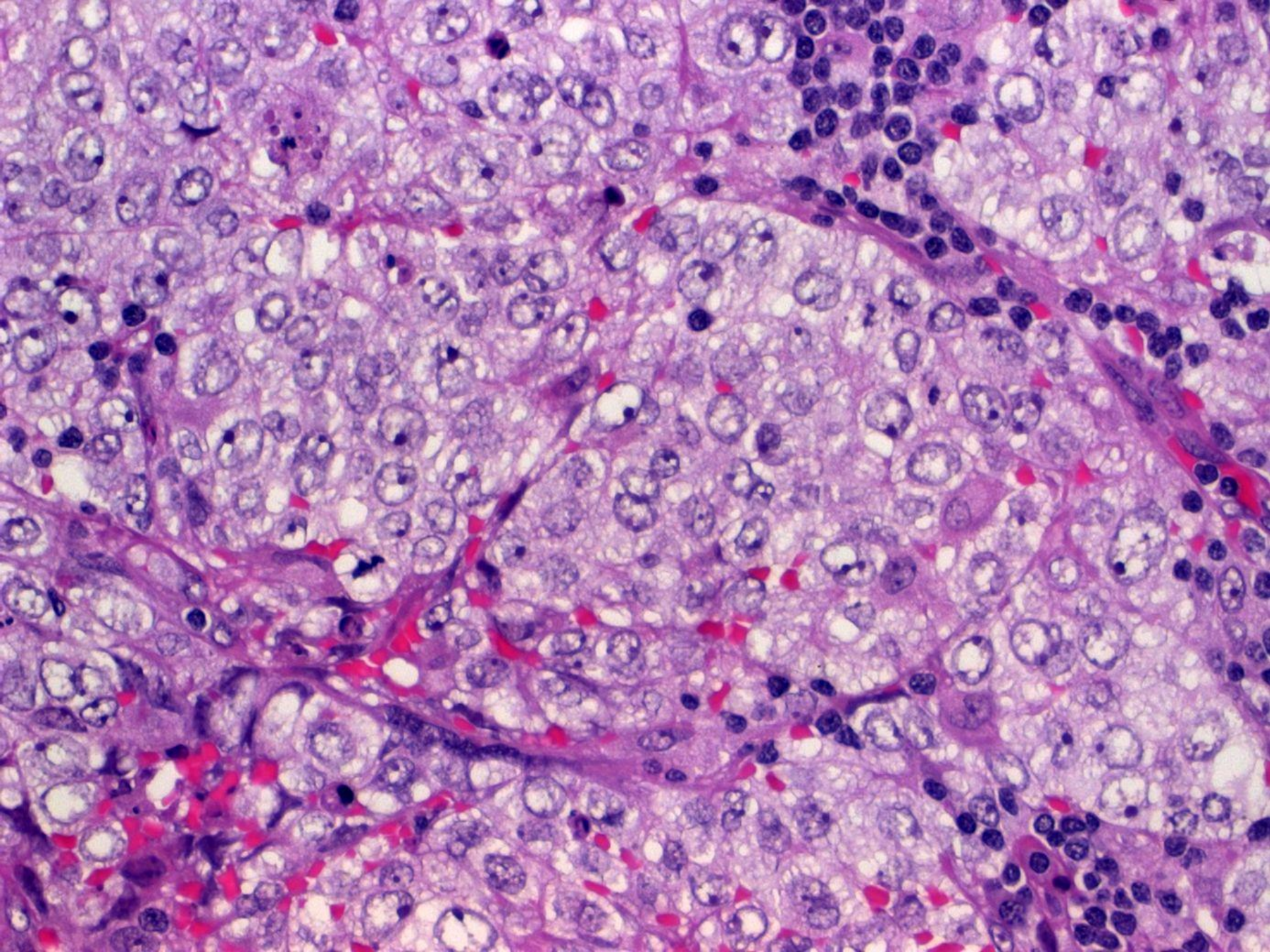
**ERG**



**58 yo male with cervical lymphadenopathy**

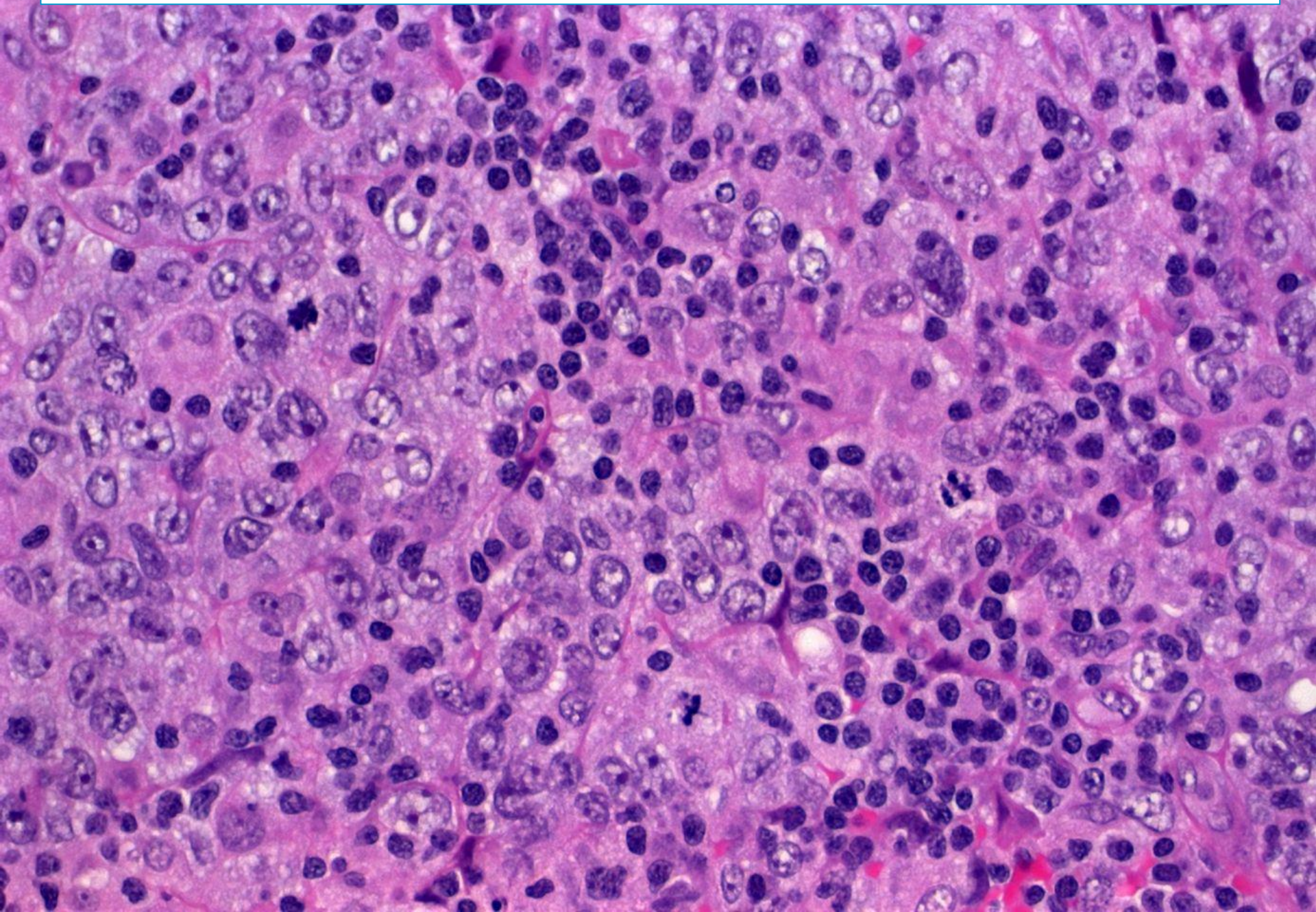






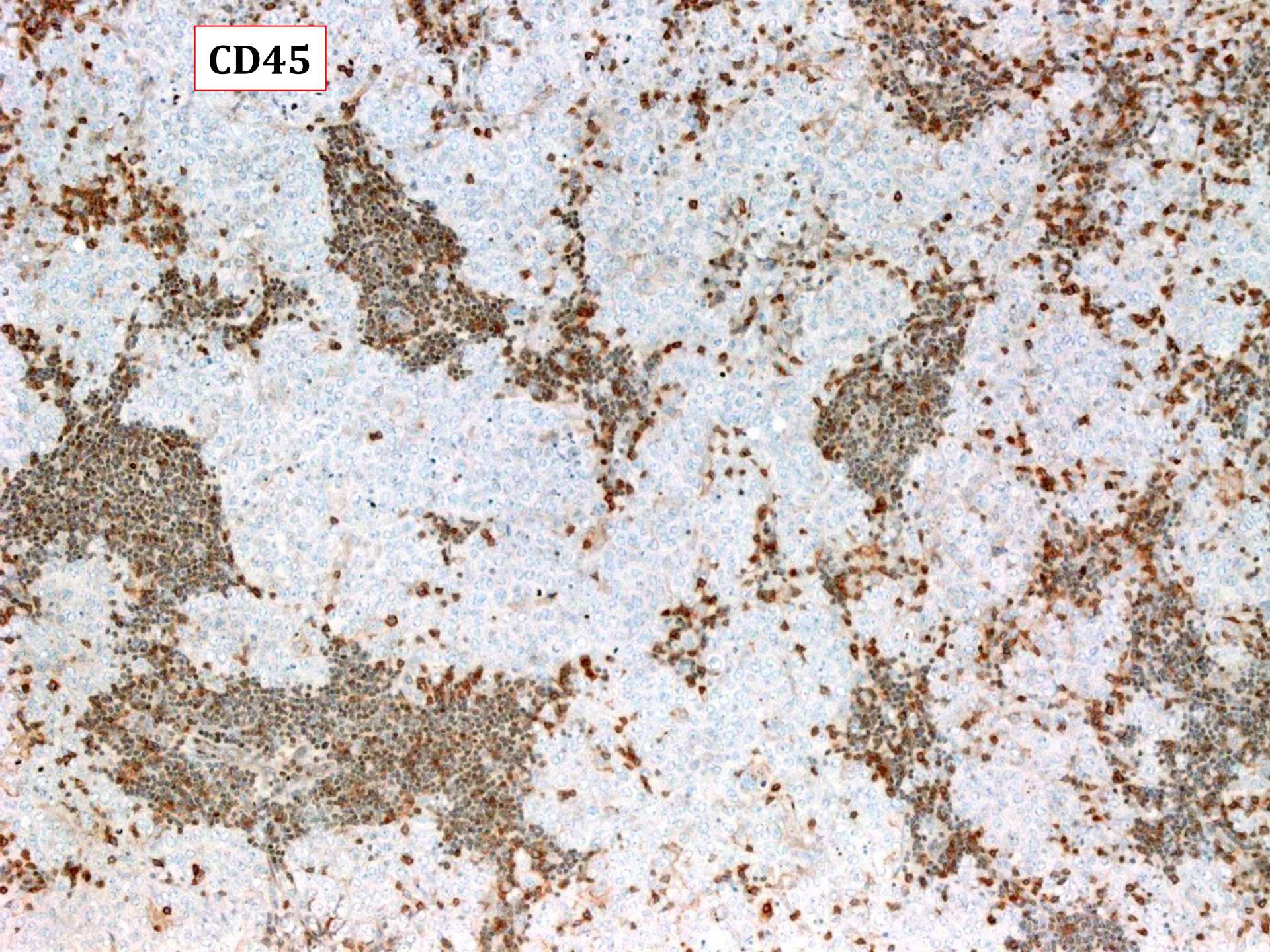


**The resident ordered CD45, p63 & p16 and then came to me**



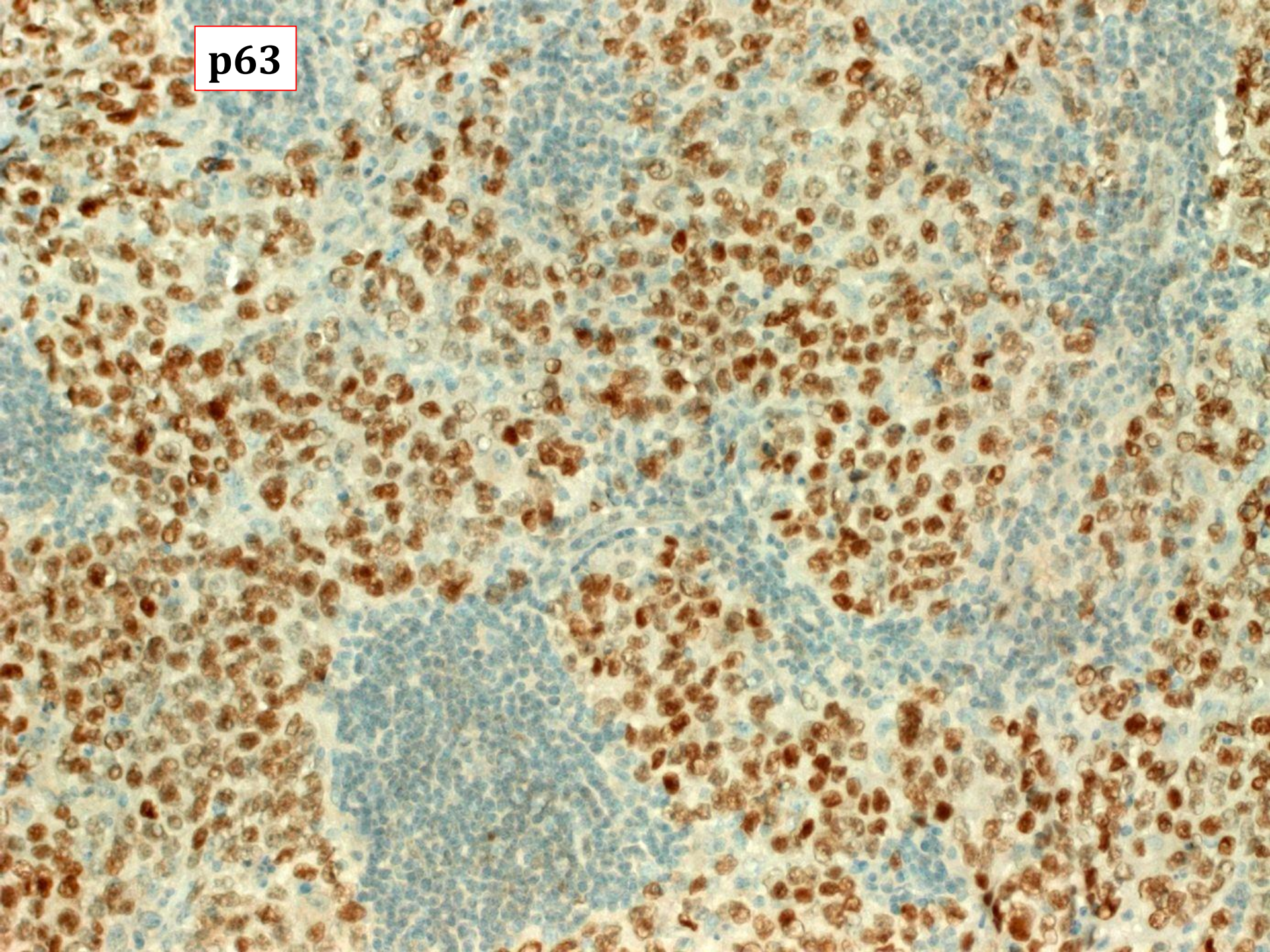


**CD45**



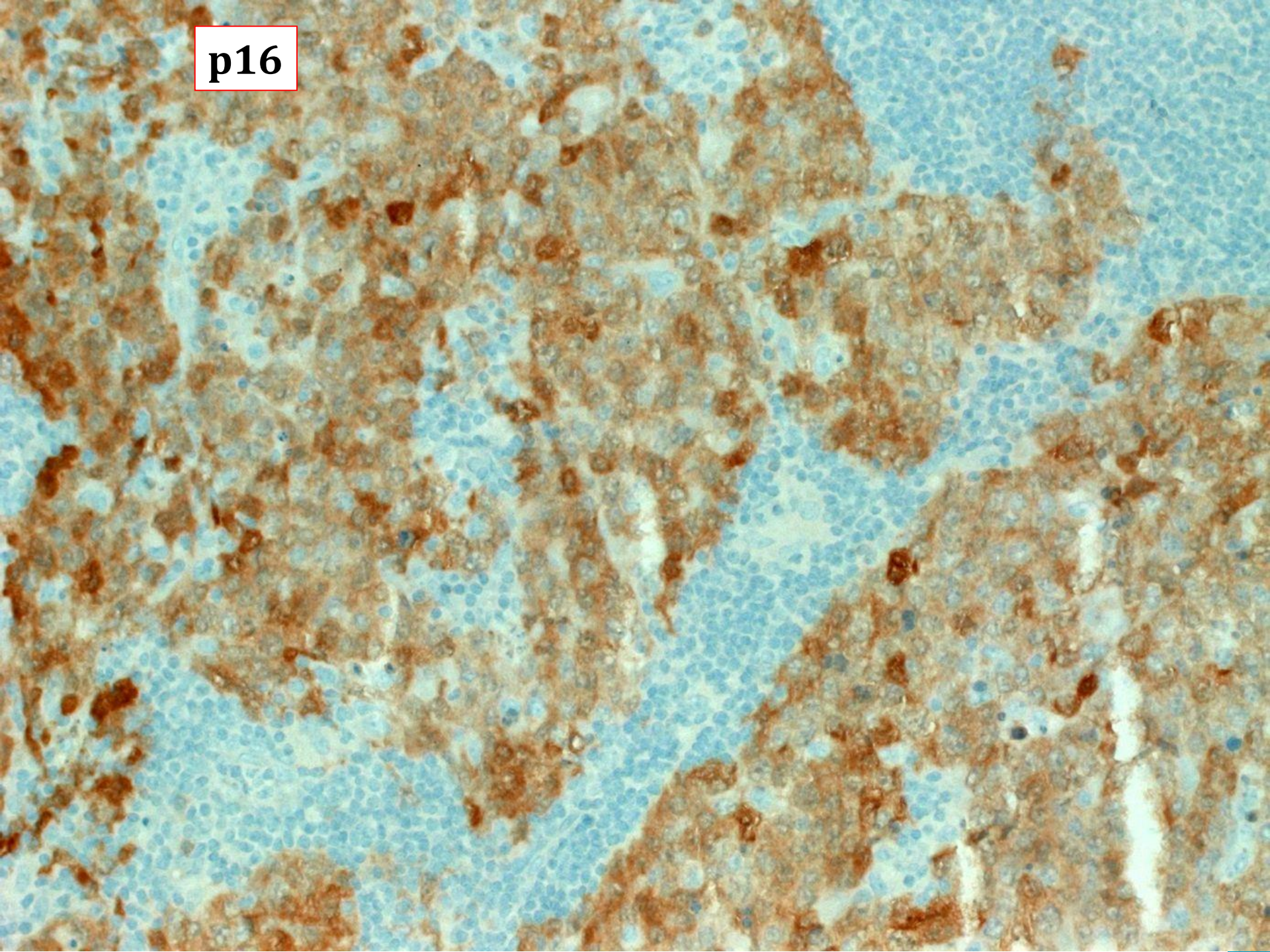


p63



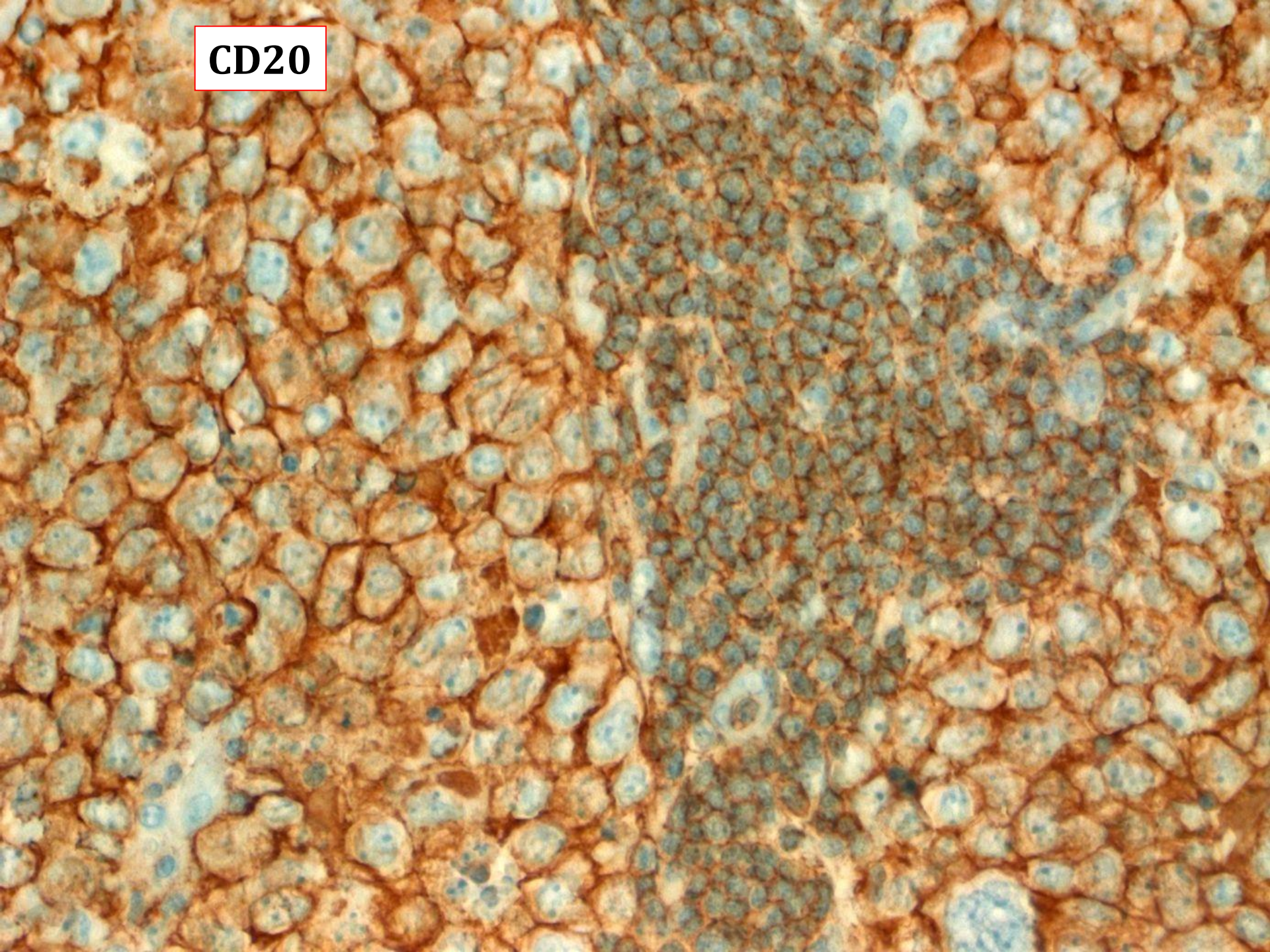


**p16**



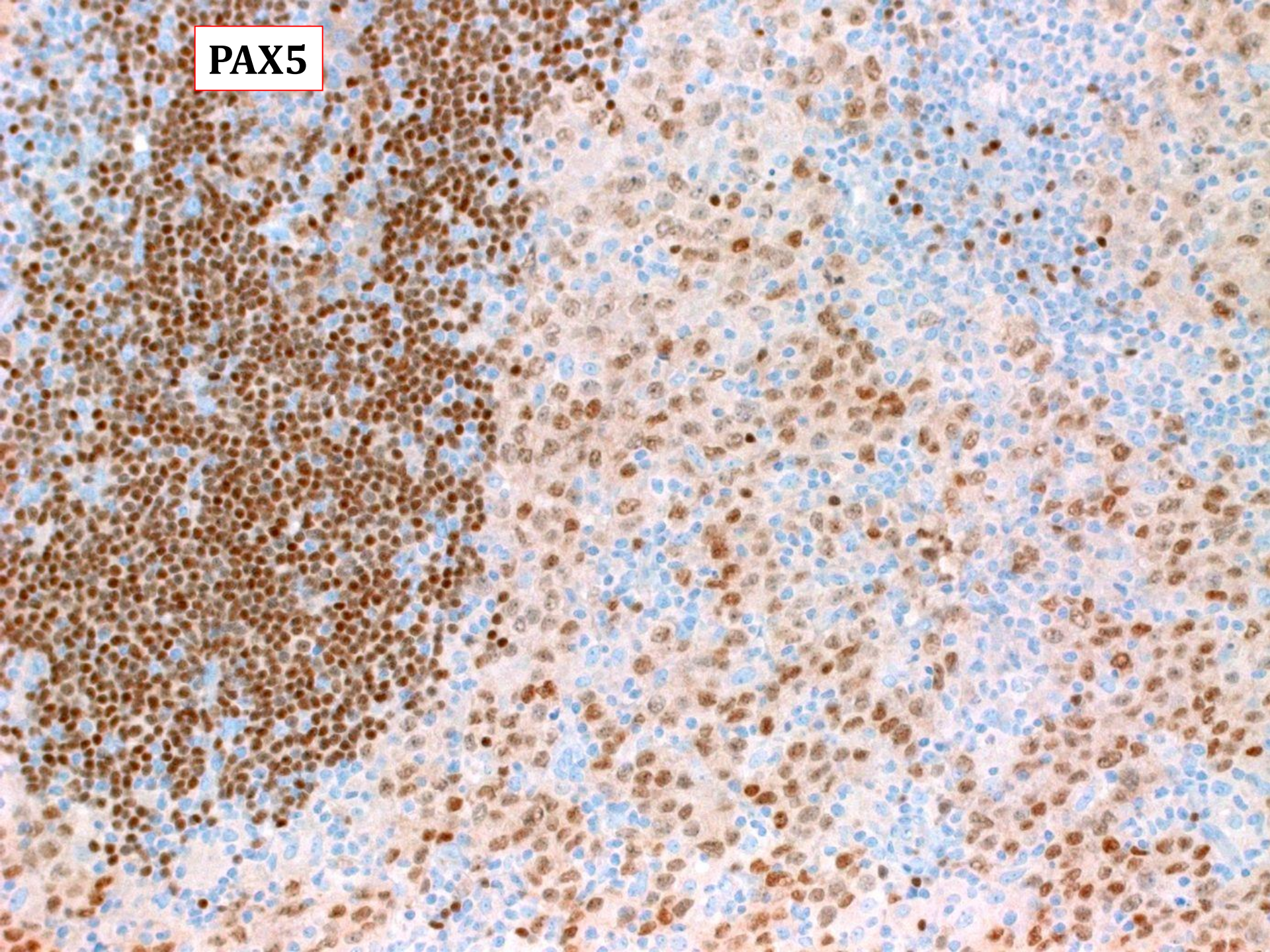


**CD20**



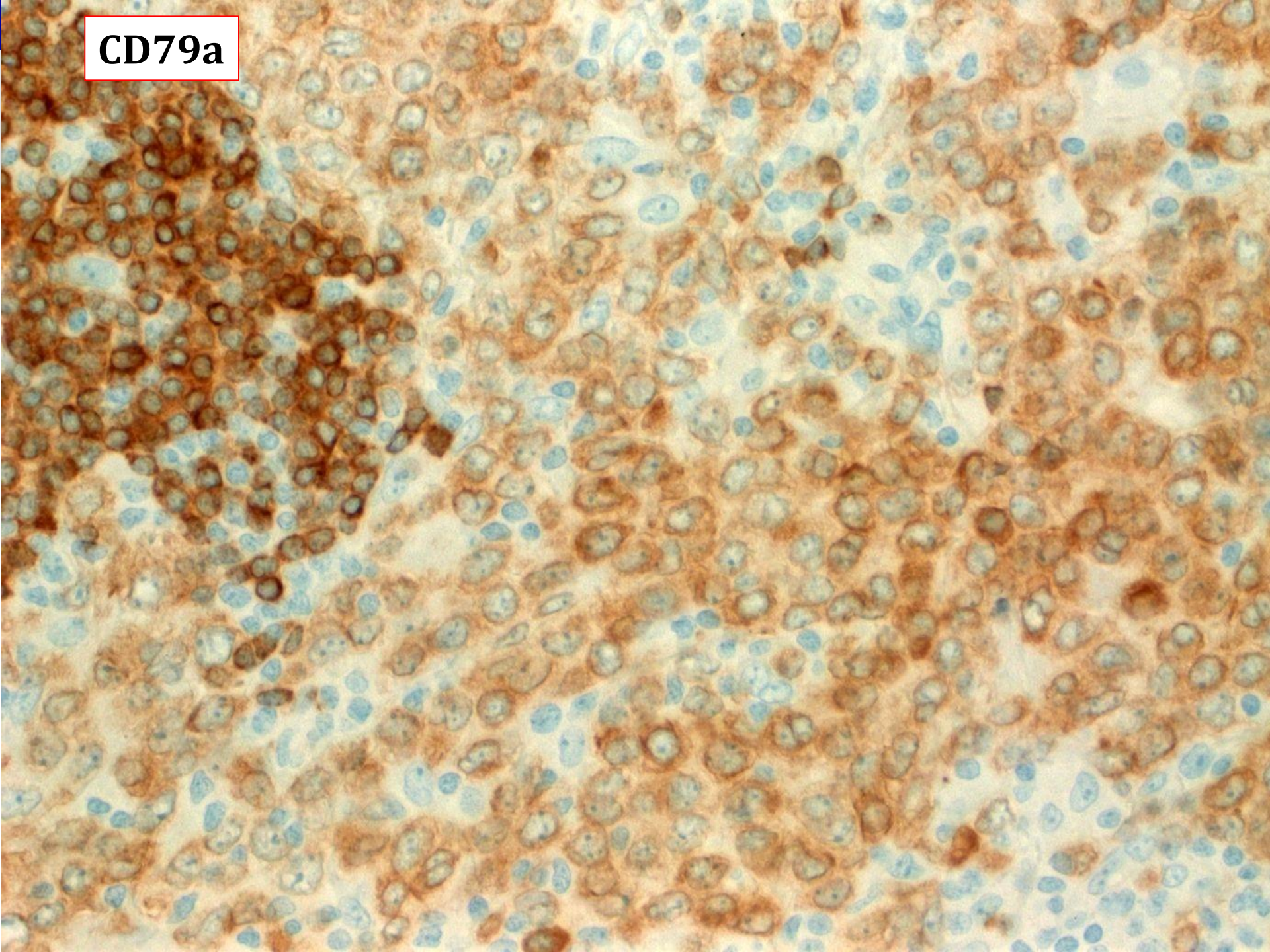


**PAX5**





**CD79a**

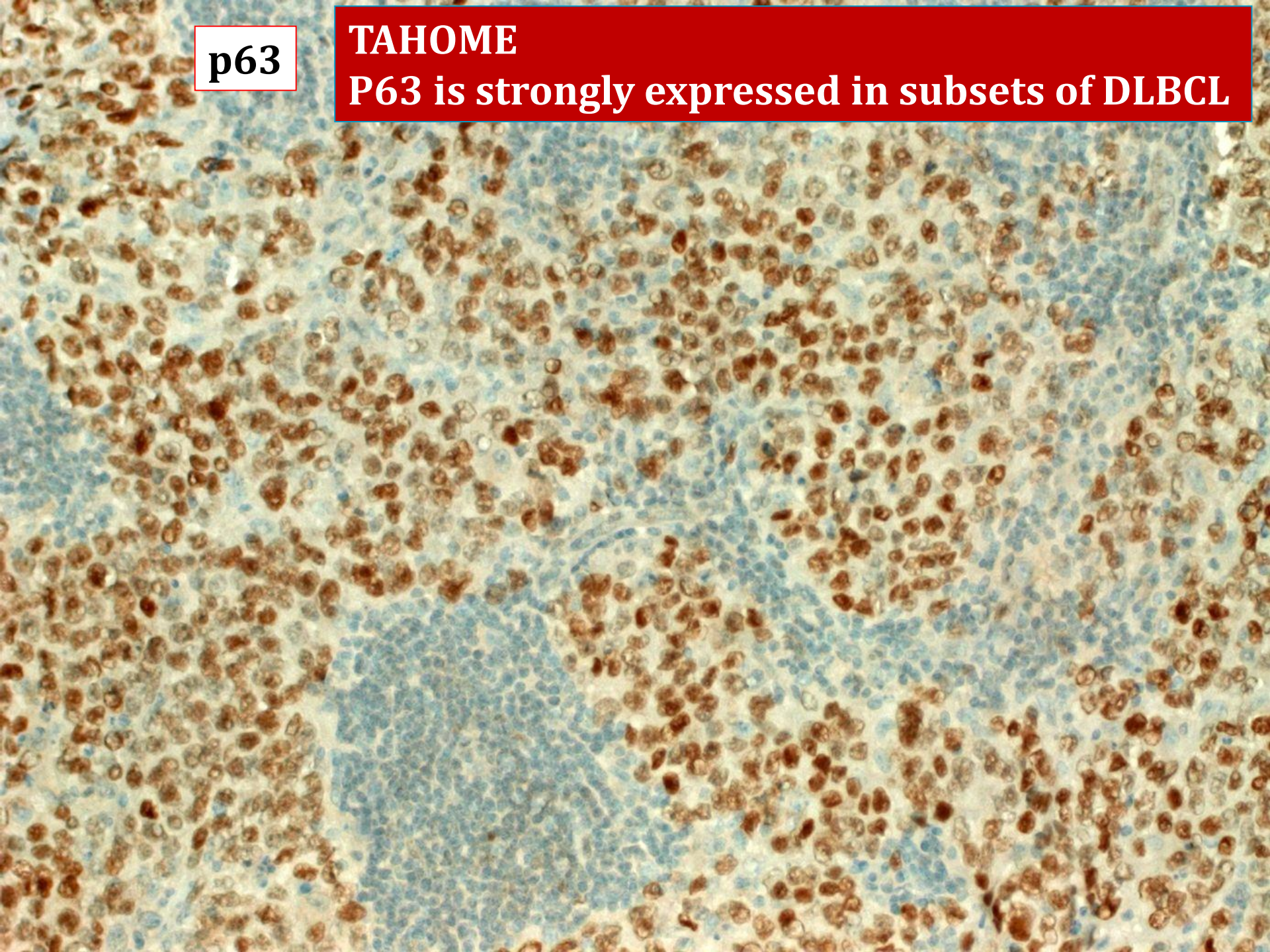




**p63**

**TAHOME**

**P63 is strongly expressed in subsets of DLBCL**

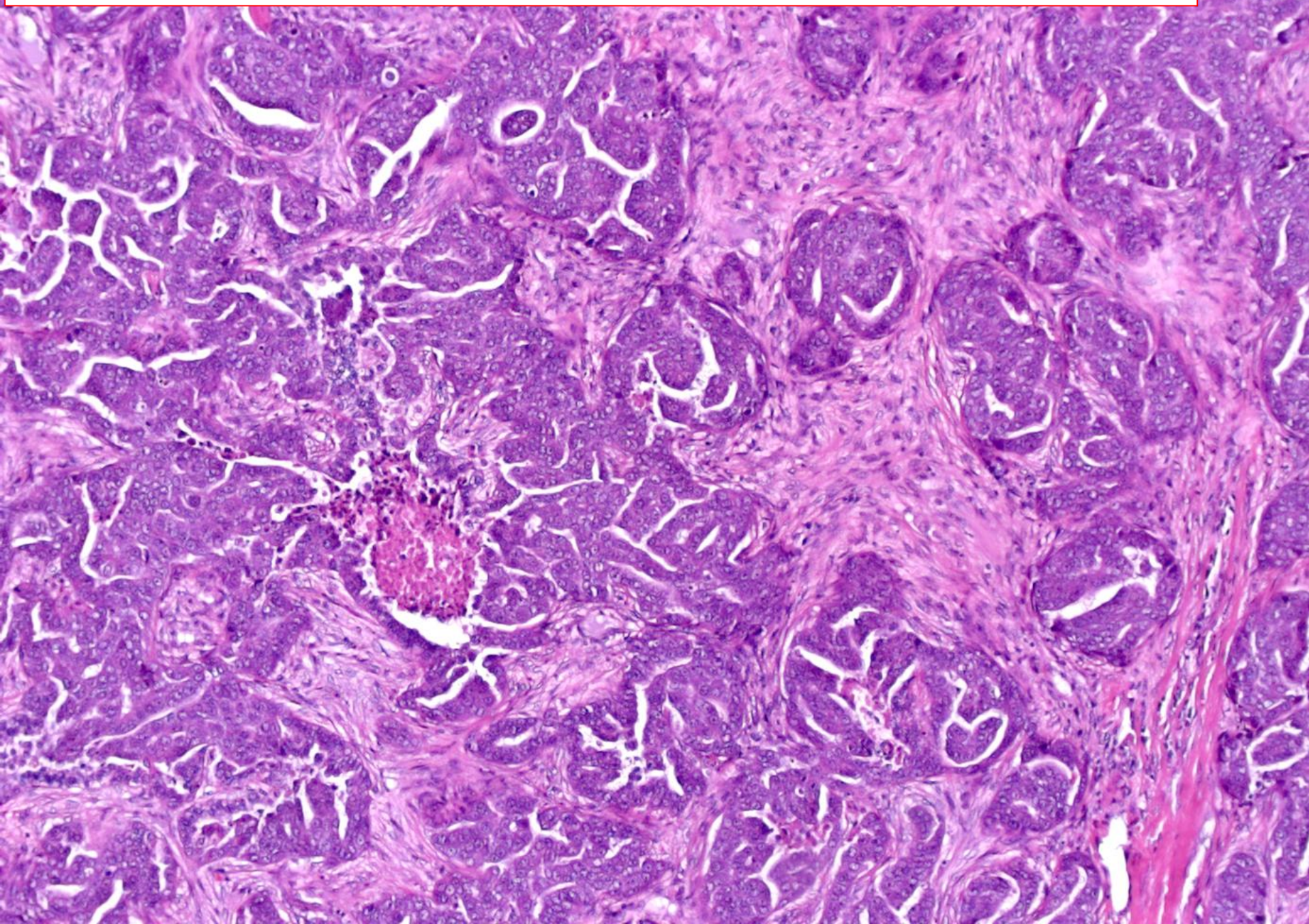




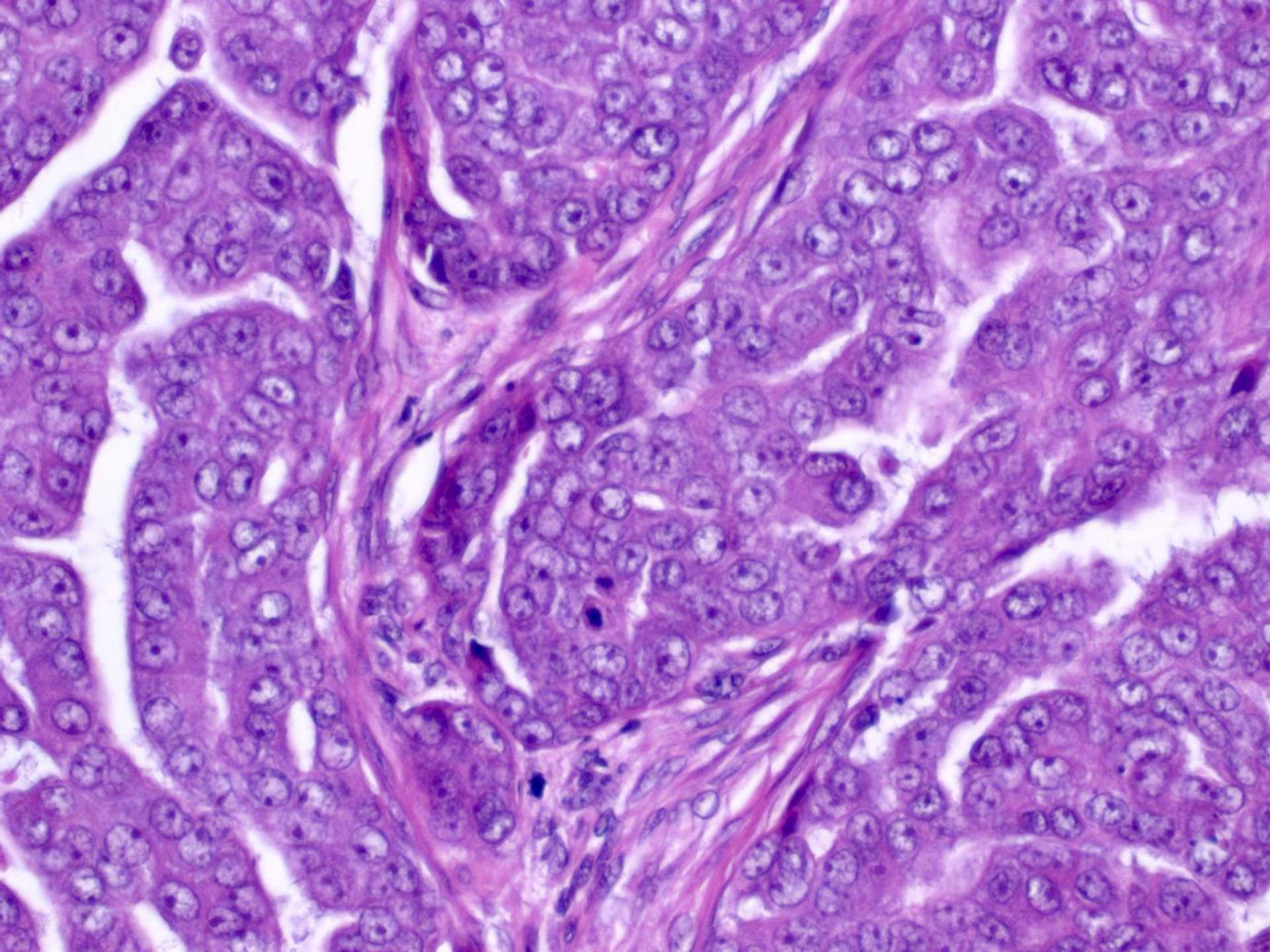




**38 yo male with 2.recurrence of submandibular gland carcinoma NOS**

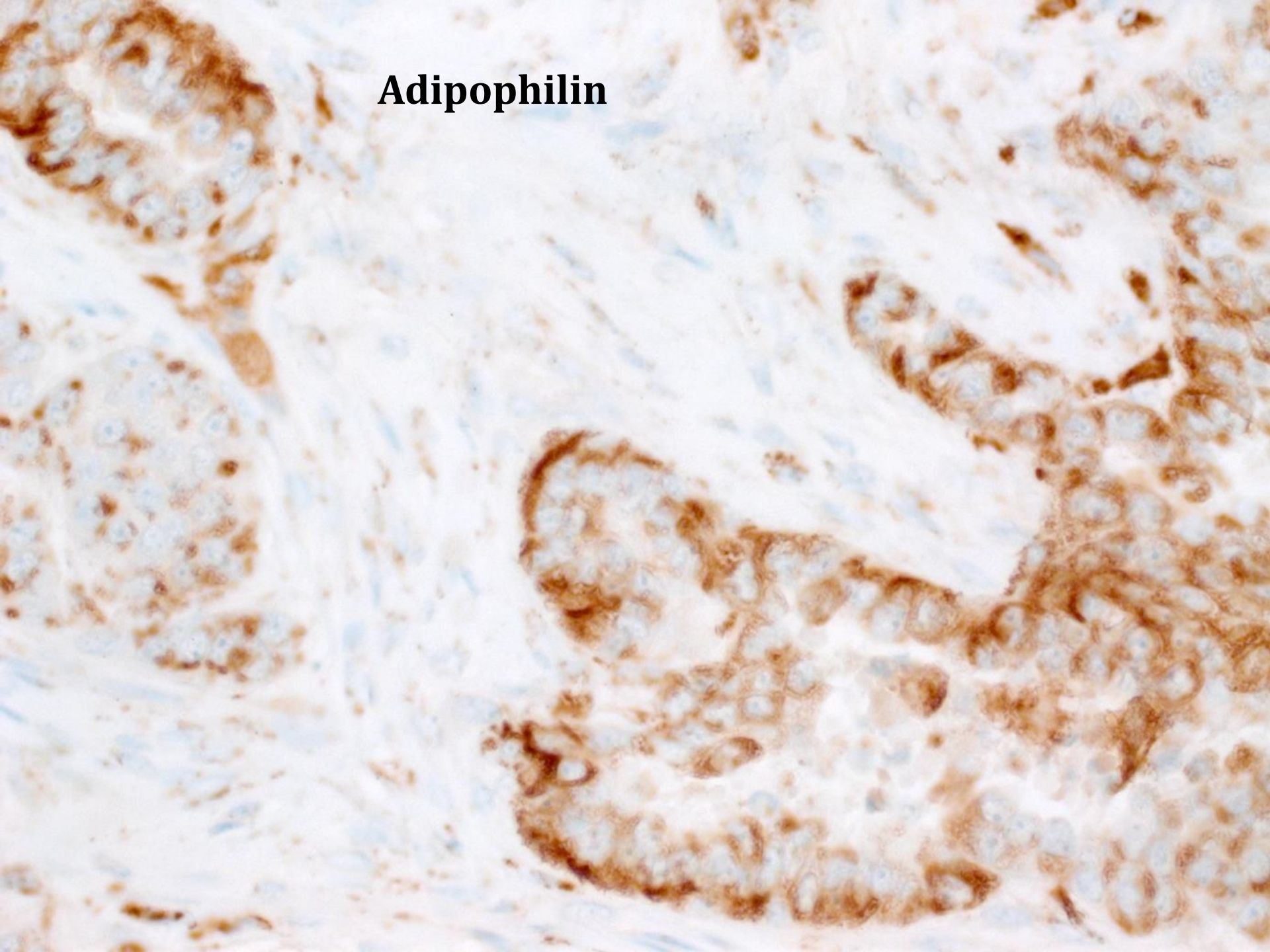




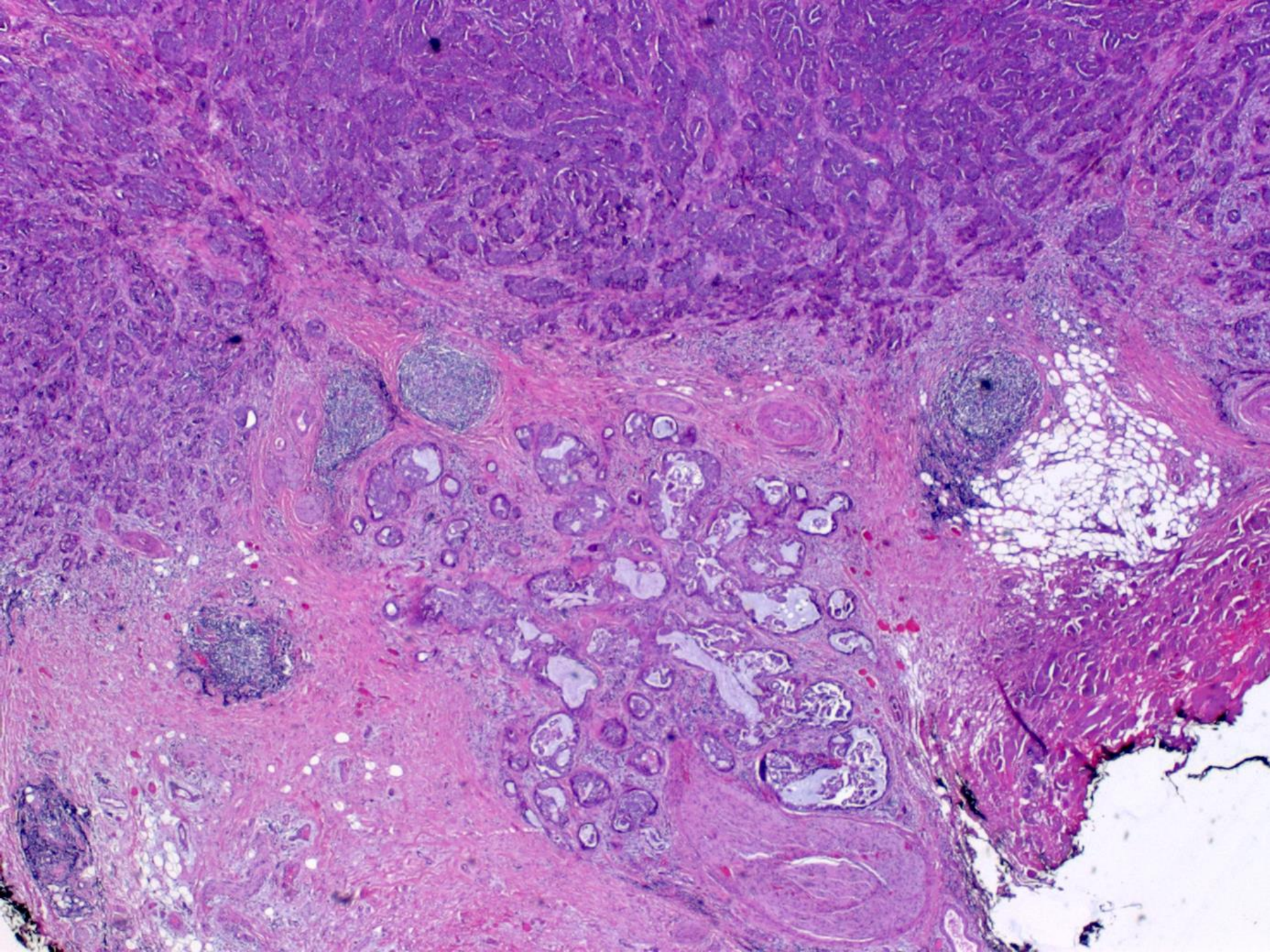




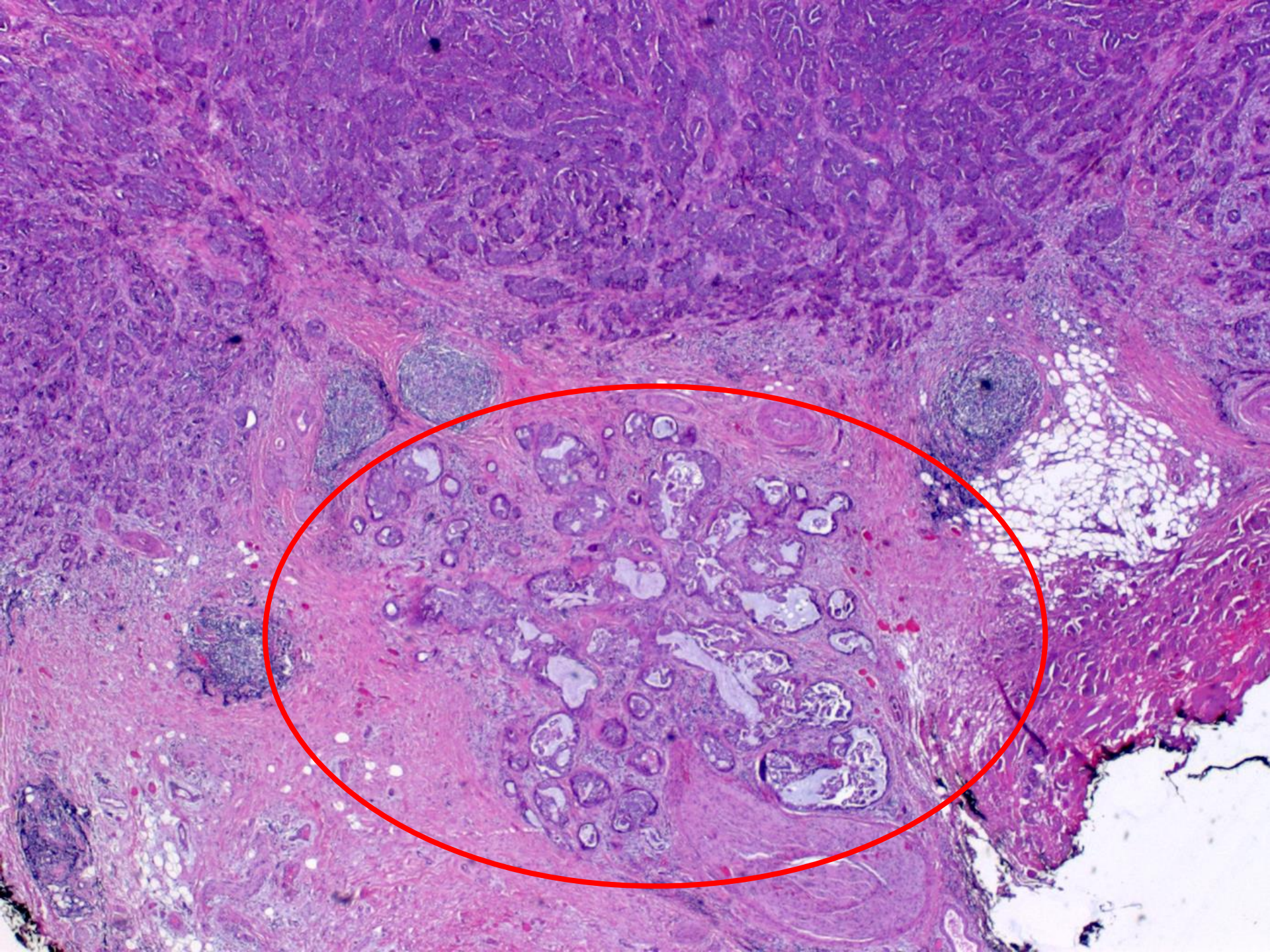
# Adipophilin





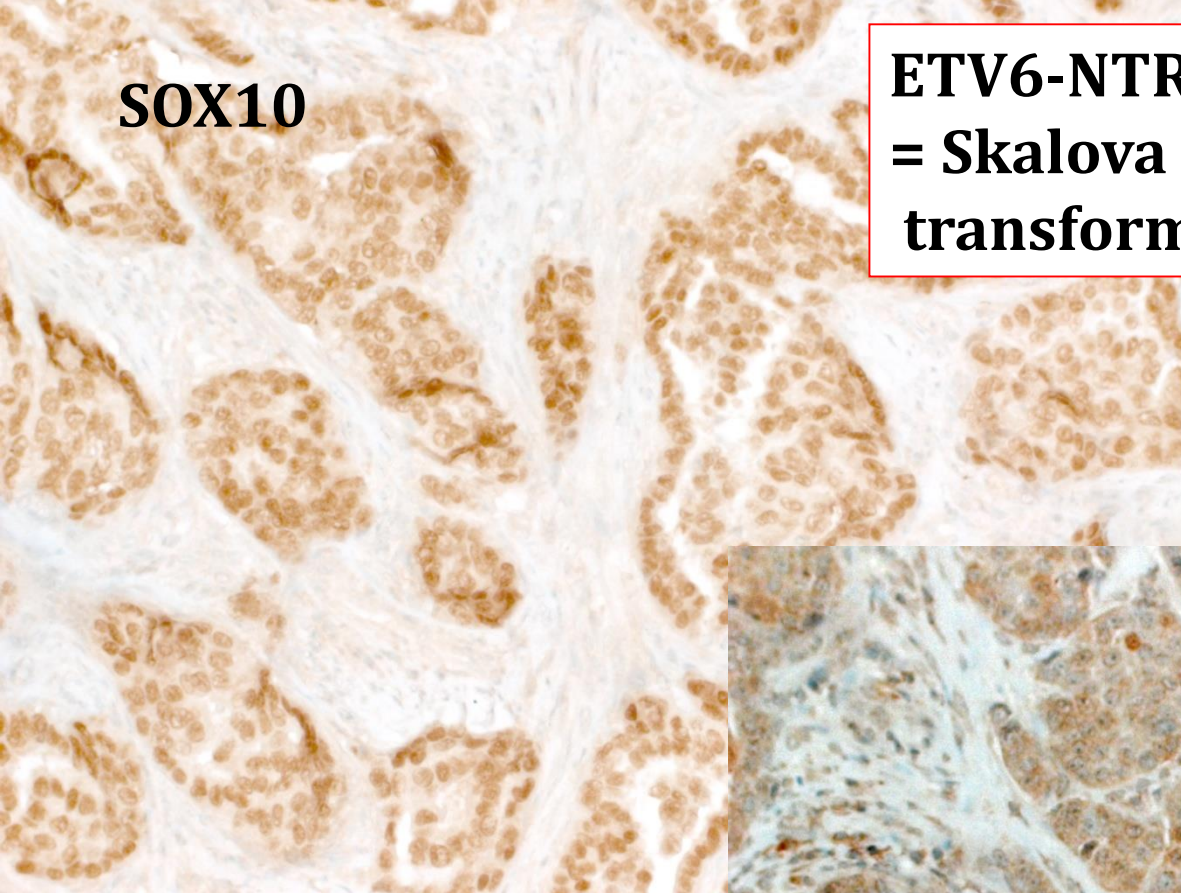






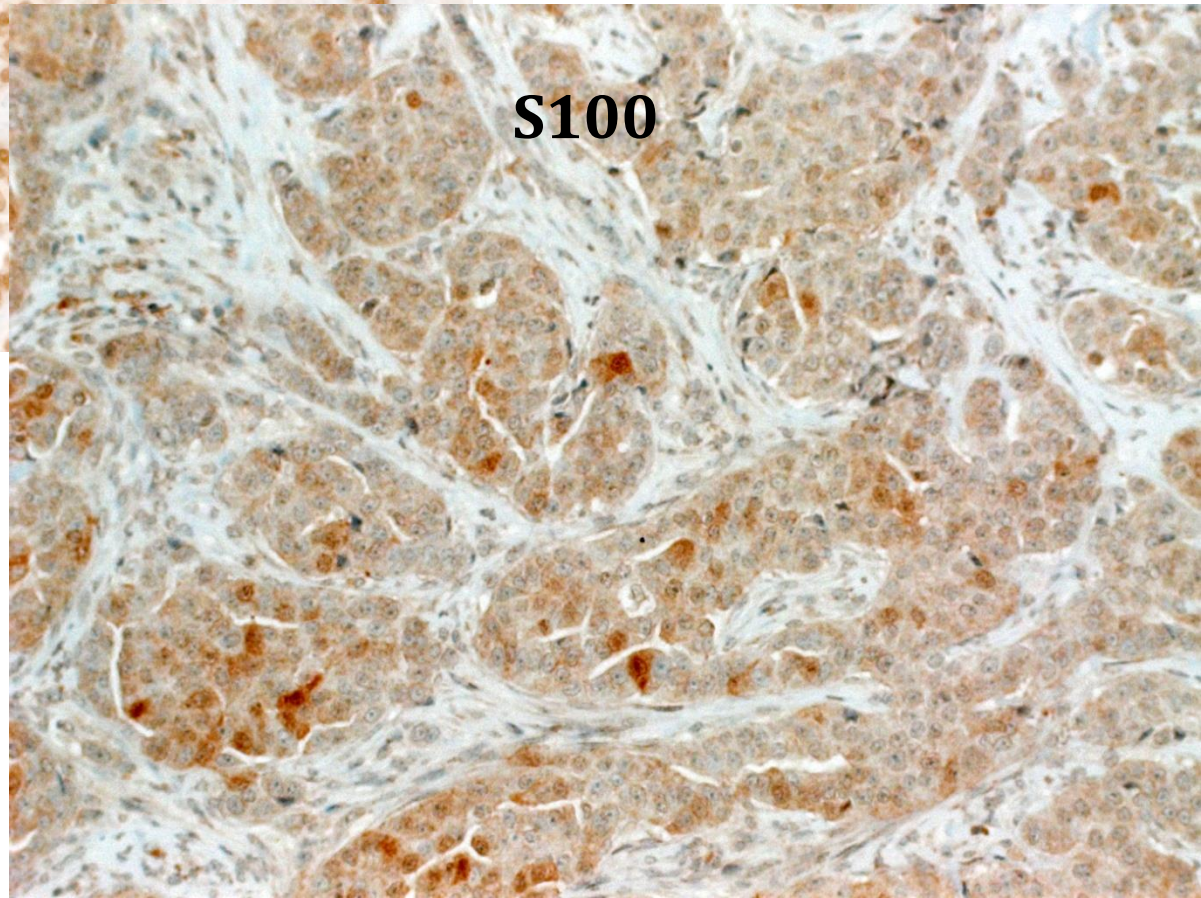


**SOX10**



**ETV6-NTRK3 confirmed by NGS  
= Skalova tumor with high-grade  
transformation**

**S100**

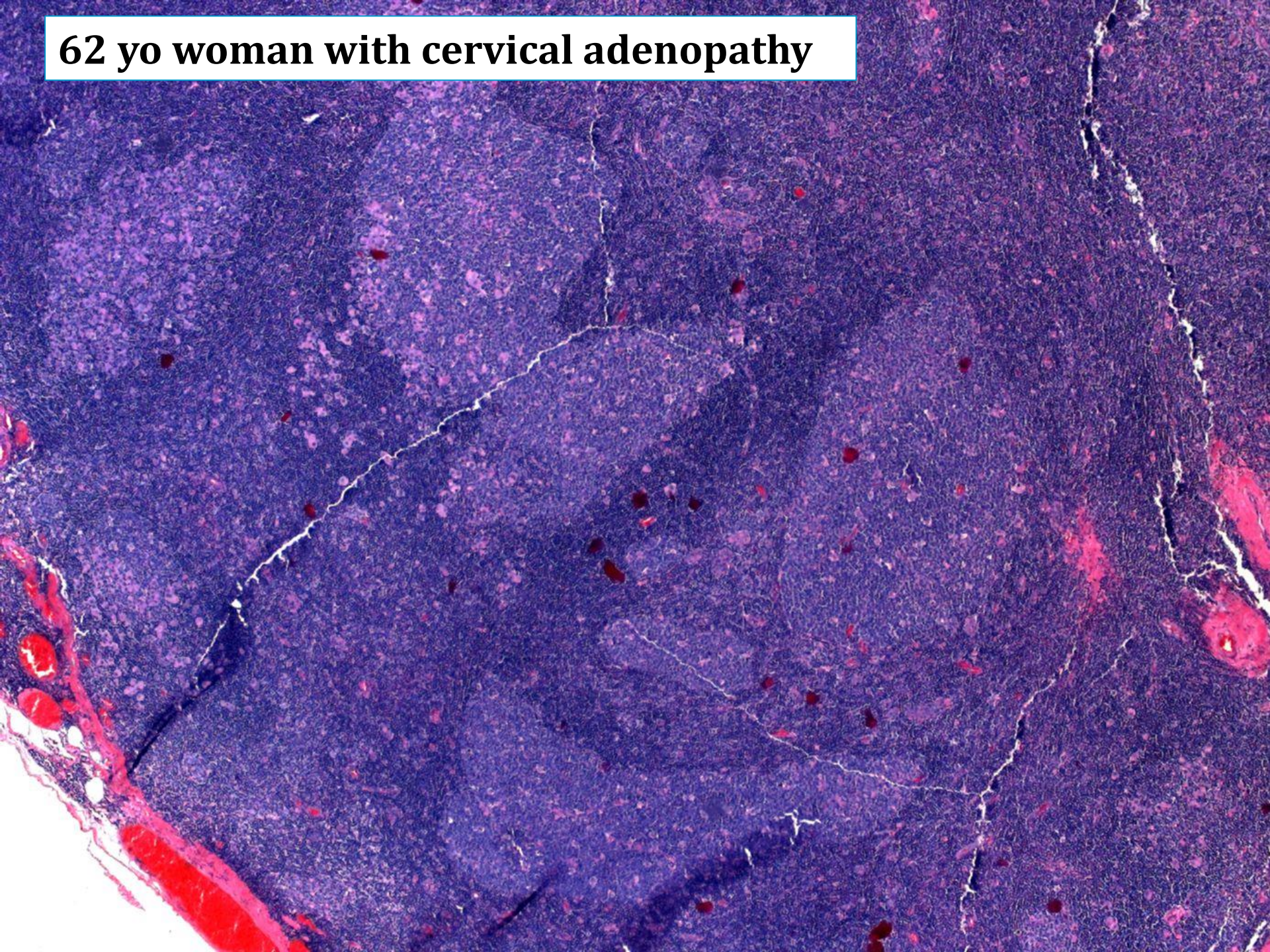



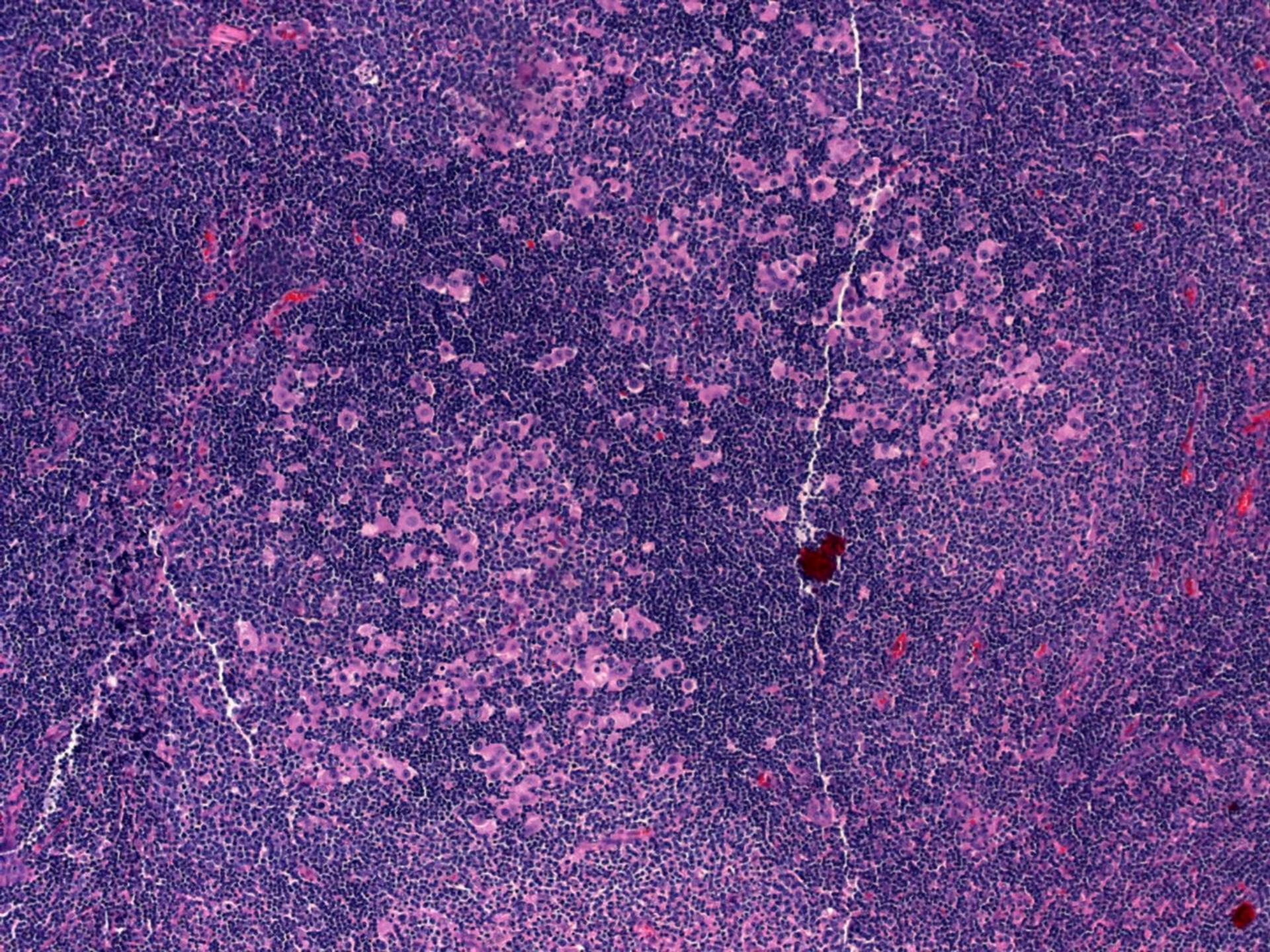




**62 yo woman with cervical adenopathy**

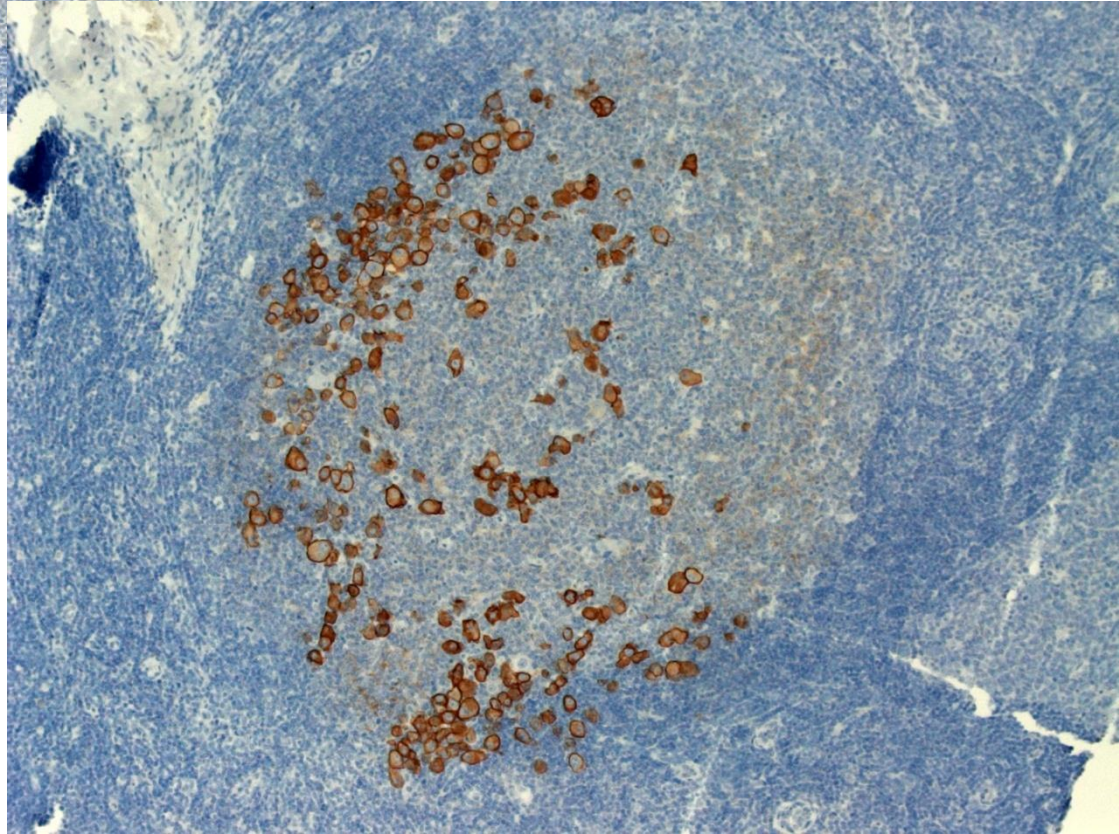
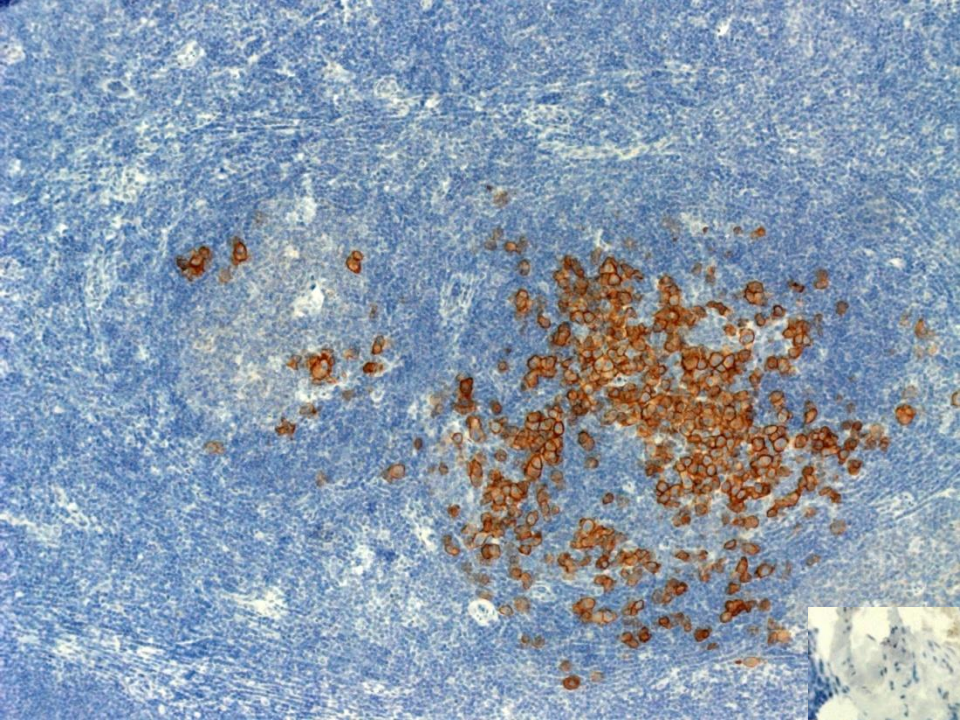






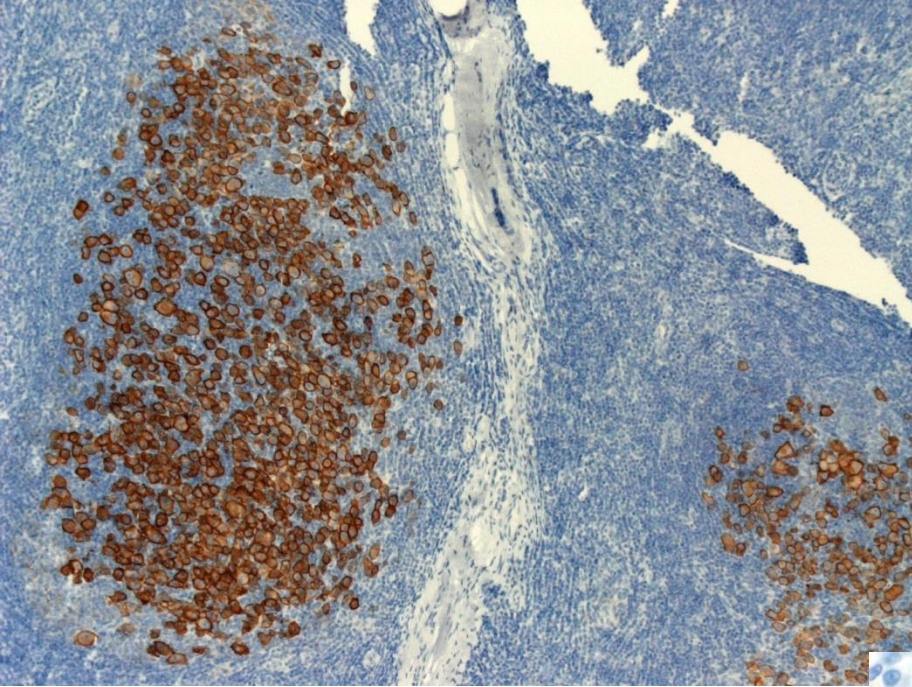


**CK**

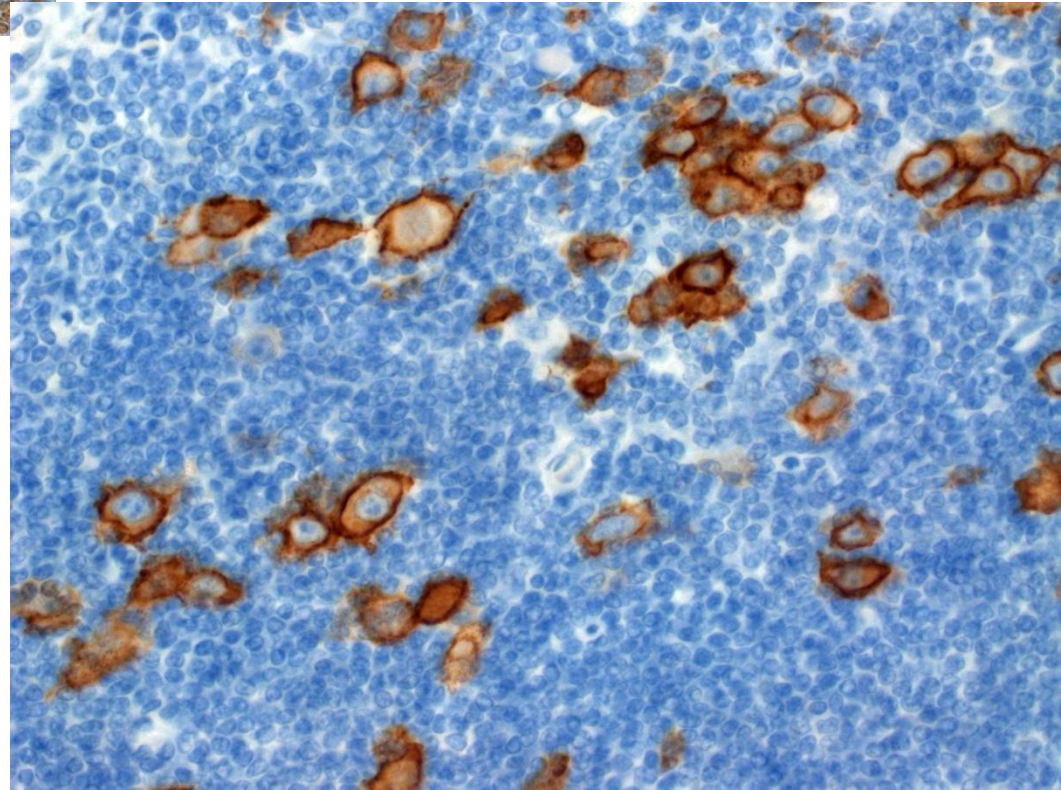




**HER2**

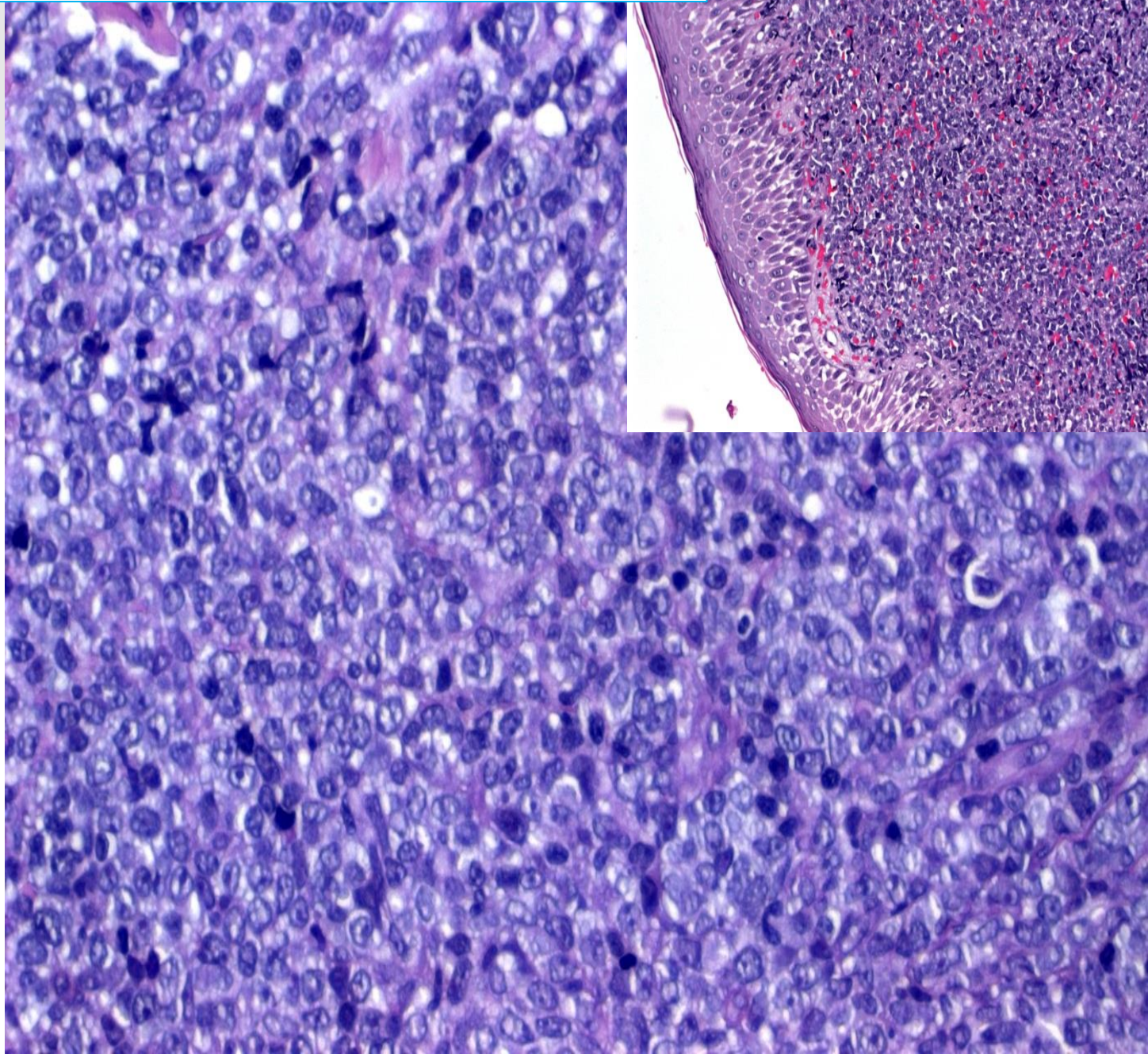


**Folliculocentric mets  
Of AR+ HER2-amplified  
Carcinoma (most likely  
salivary)**





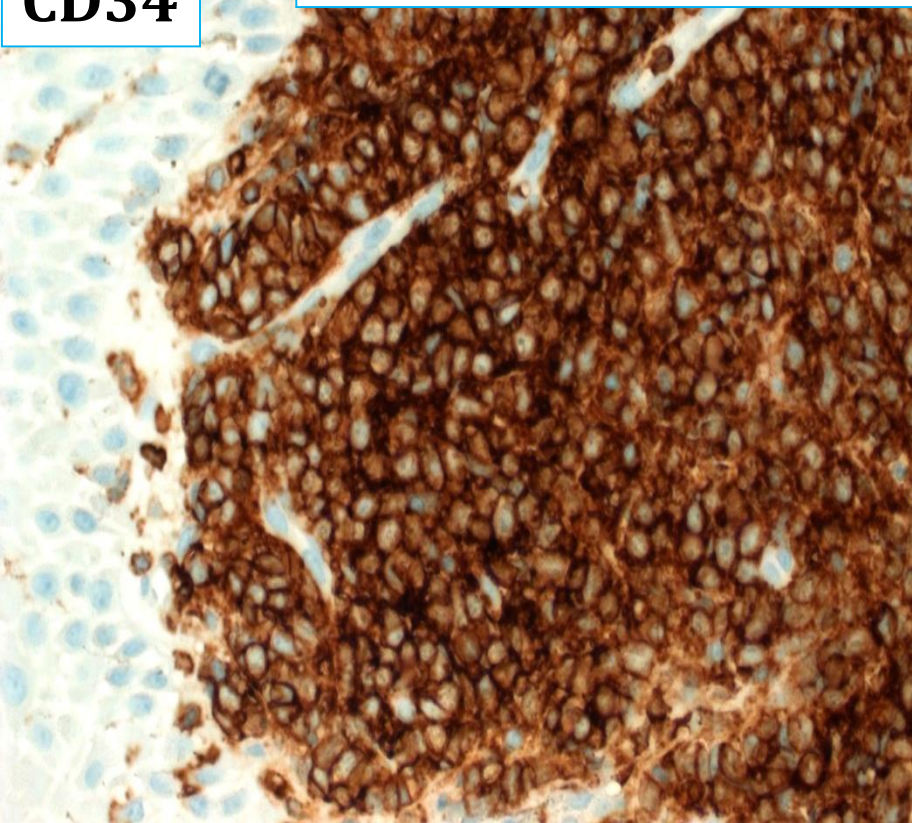
**74 yo male with erythematous skin nodule**



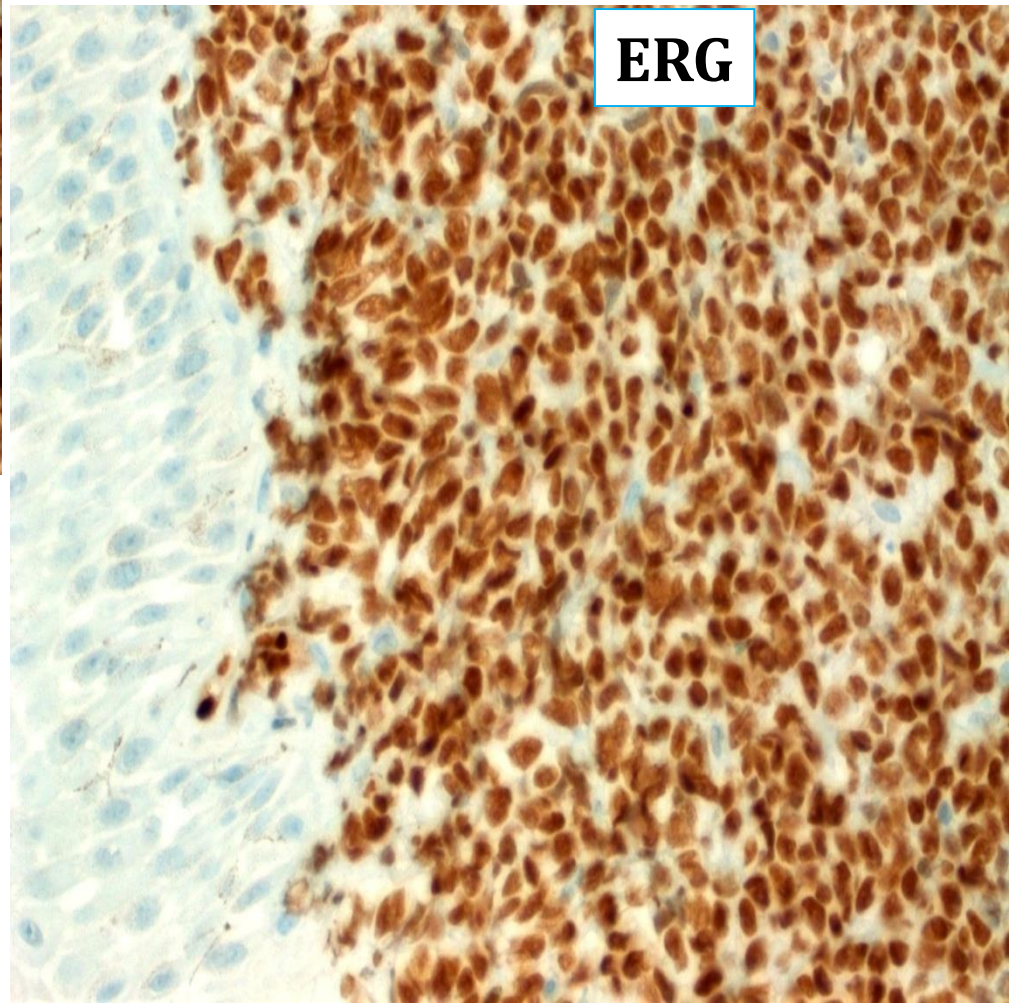


74 yo male with erythematous skin nodule

CD34



ERG

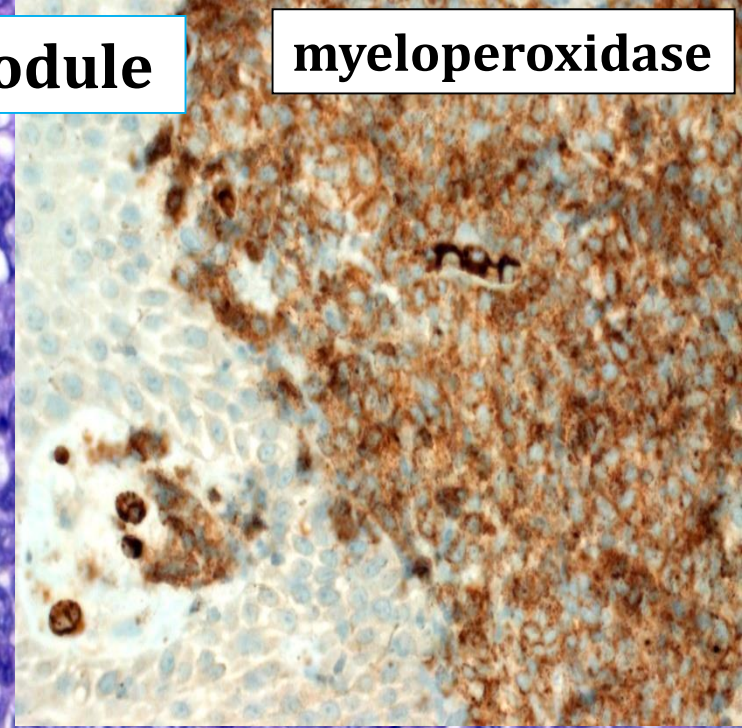
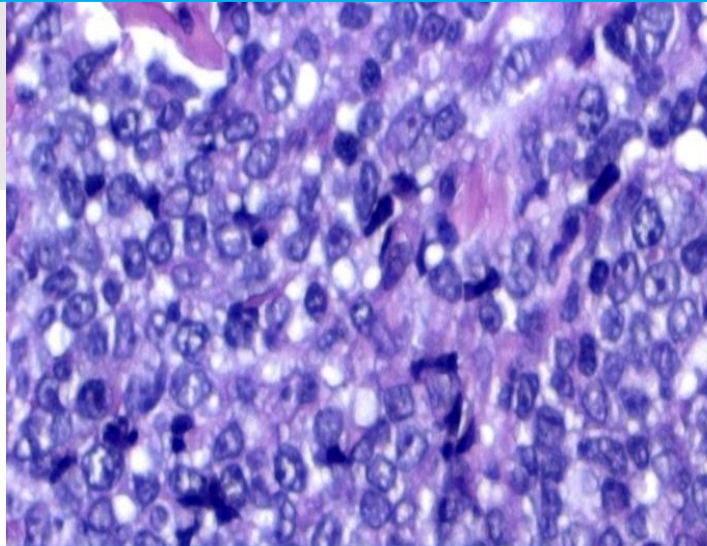




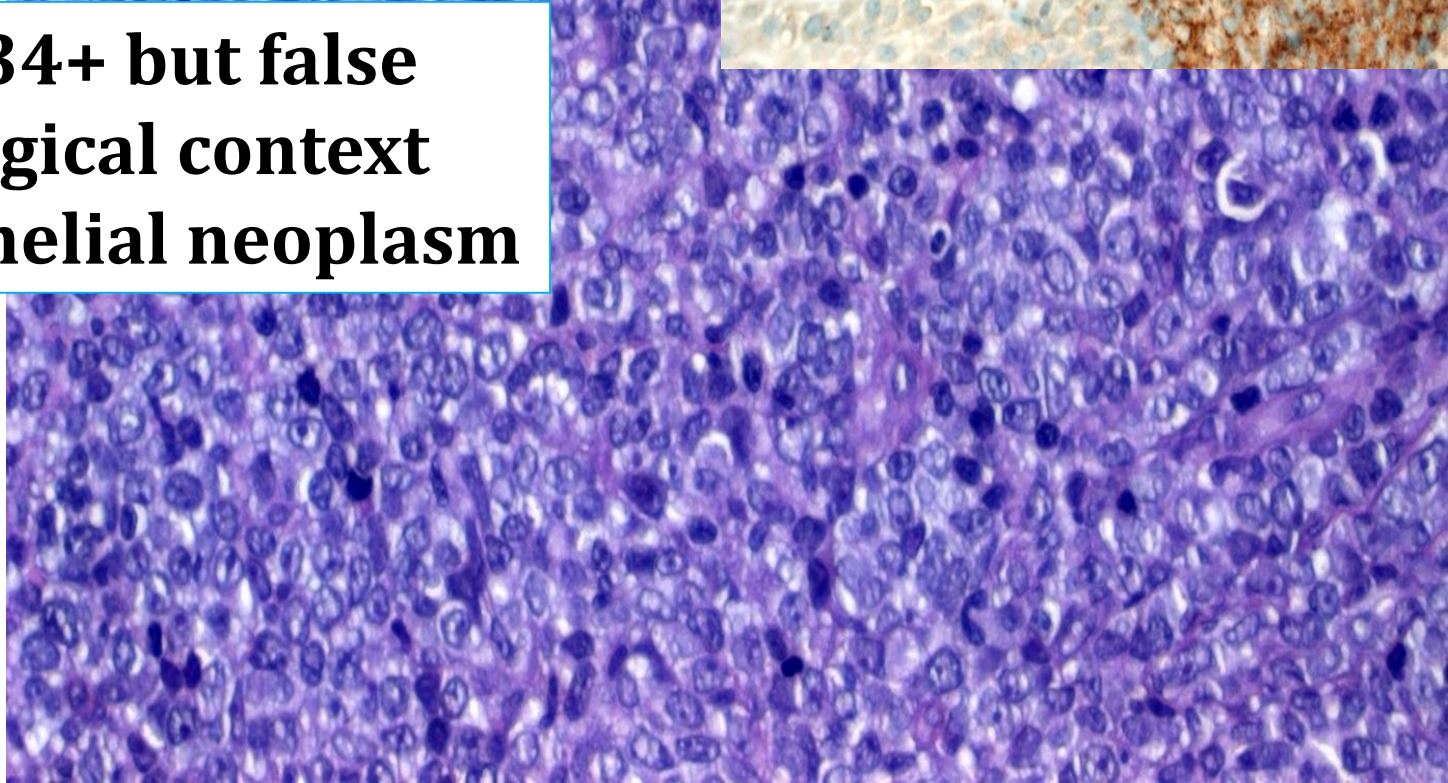
**74 yo male with erythematous skin nodule**

**myeloperoxidase**

**AML  
chloroma**

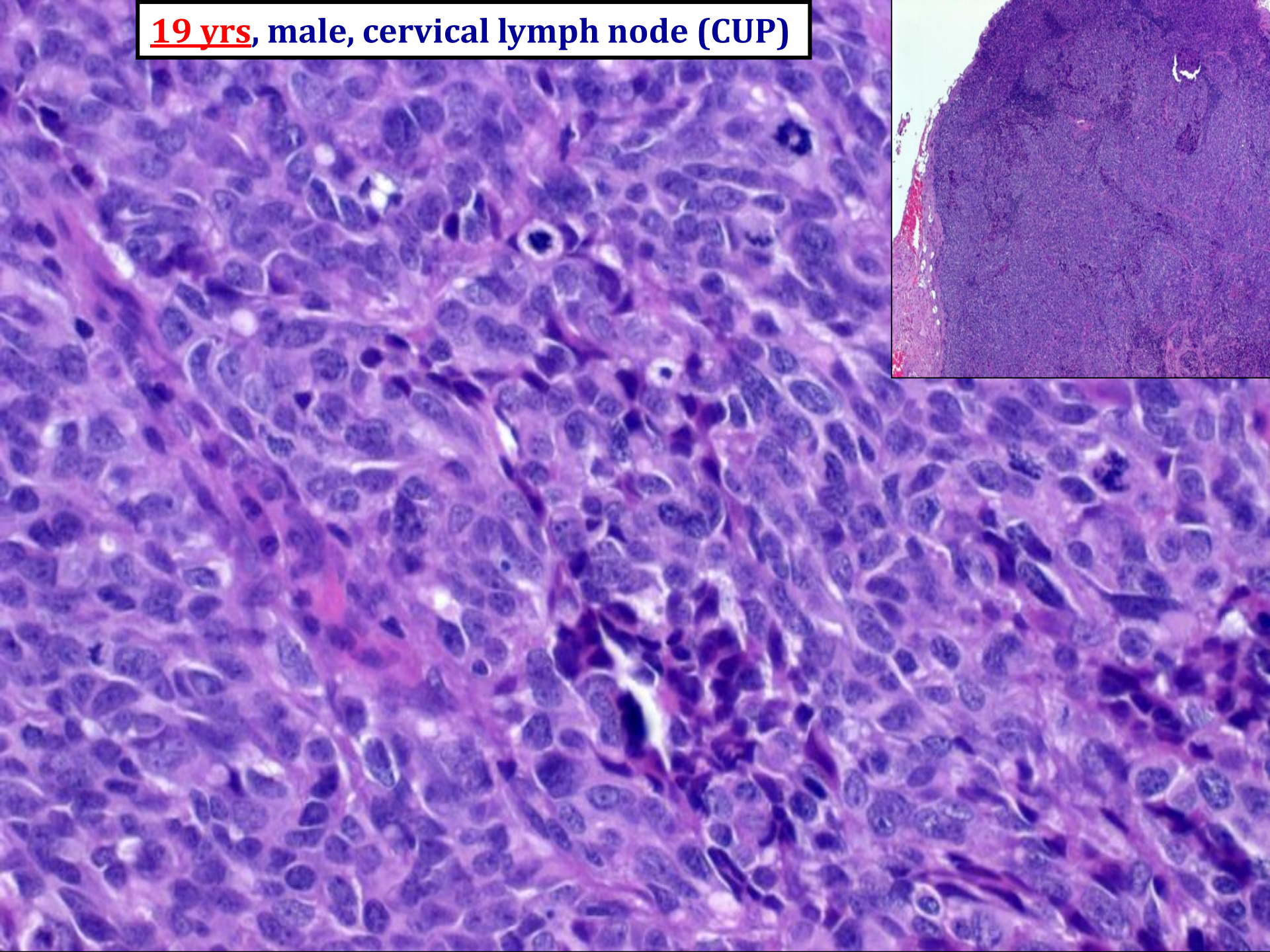


**ERG+/CD34+ but false  
morphological context  
for endothelial neoplasm**



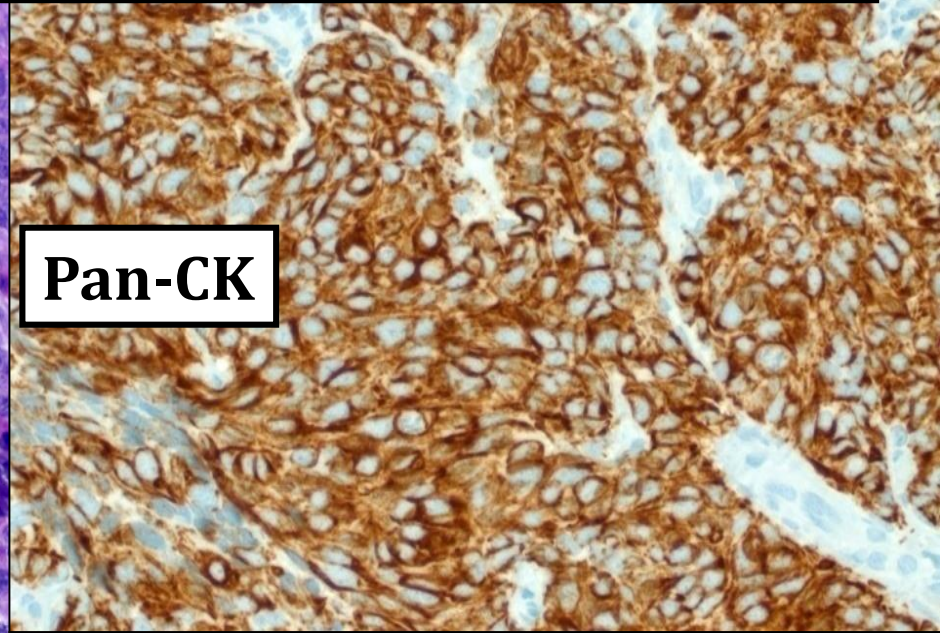
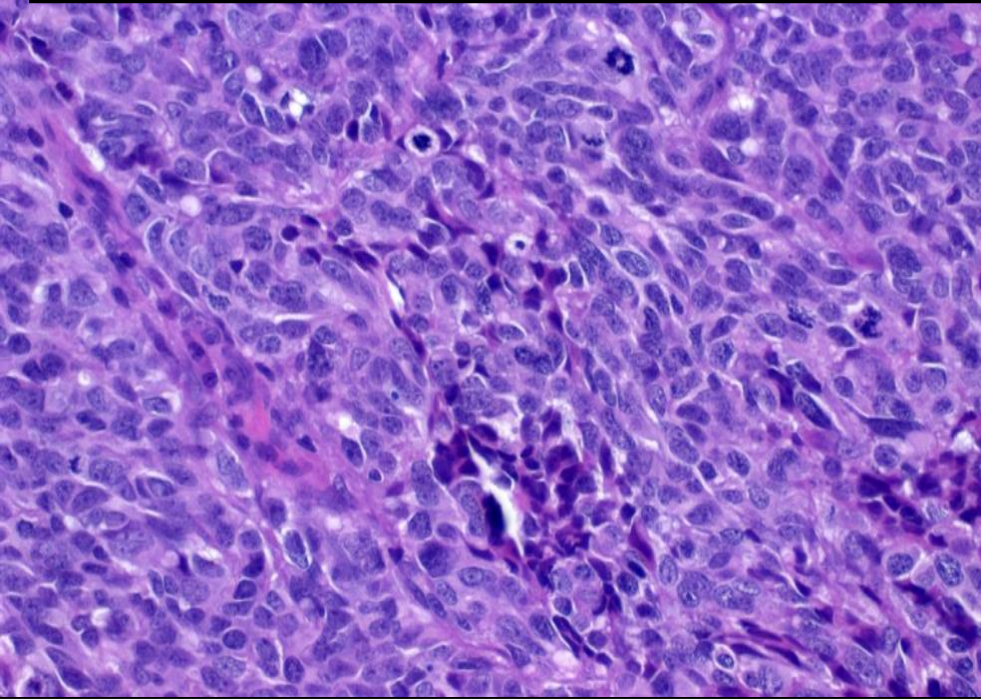


**19 yrs, male, cervical lymph node (CUP)**

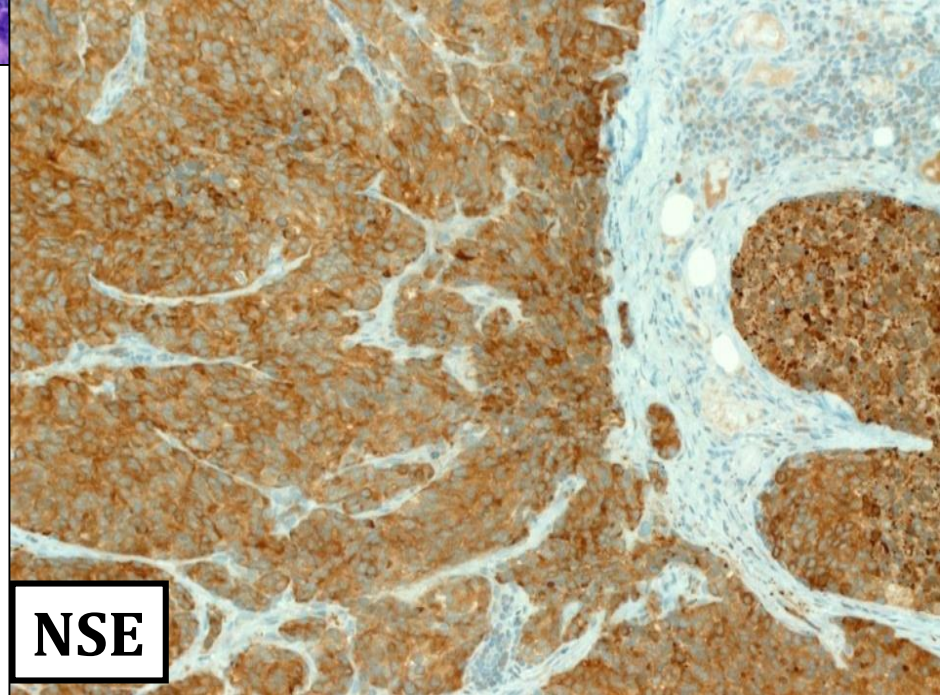




**19 yrs, male, cervical node mets referred as poorly diff carcinoma (CUP)**



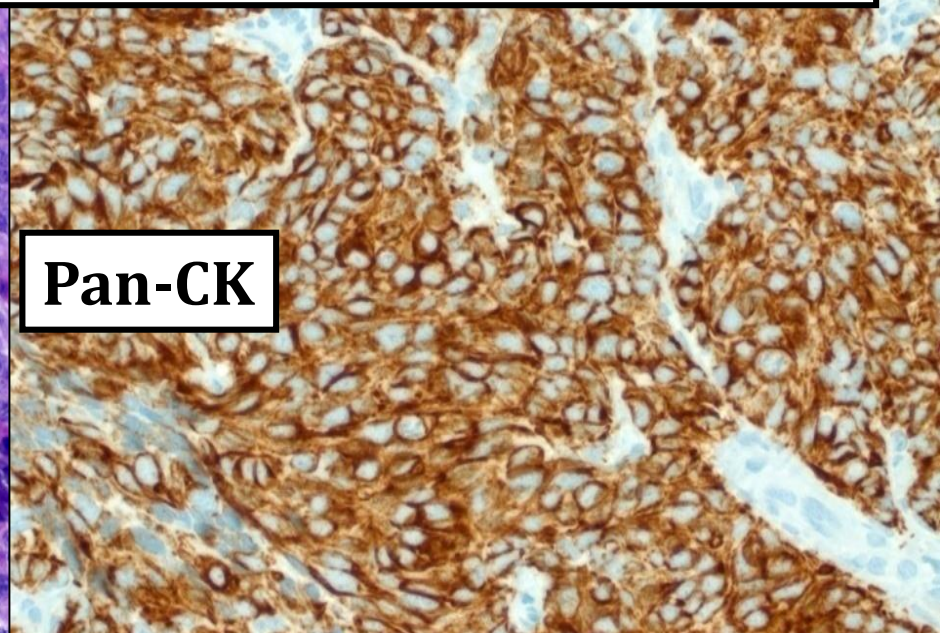
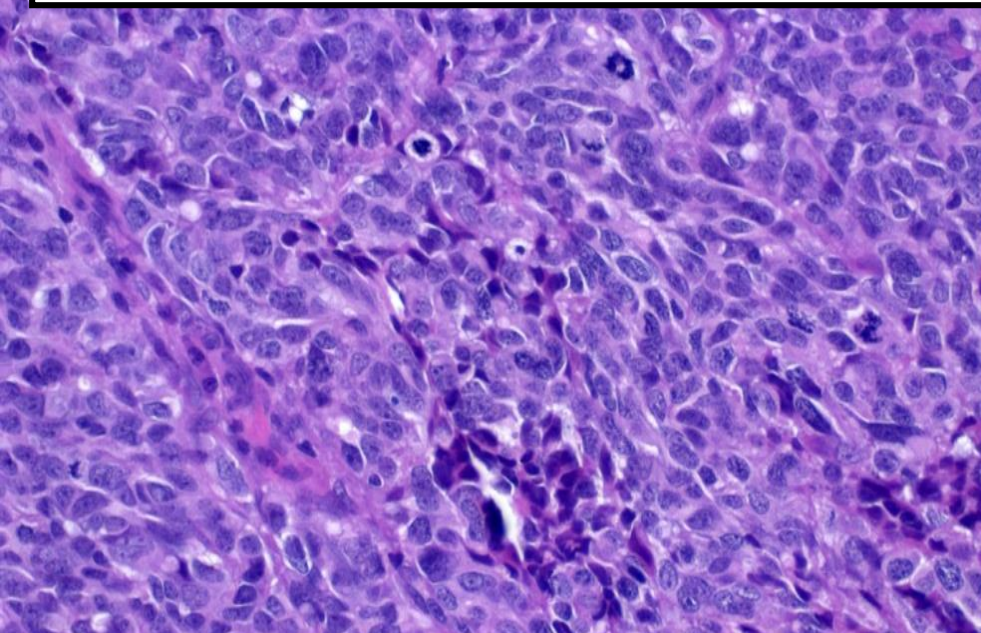
**Pan-CK**



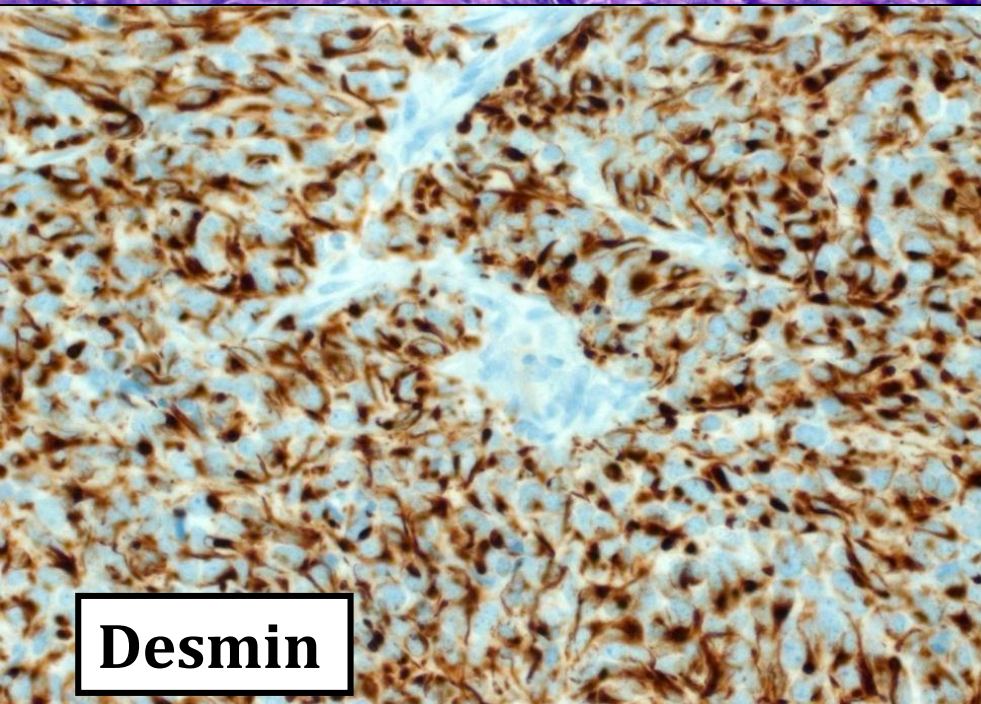
**NSE**



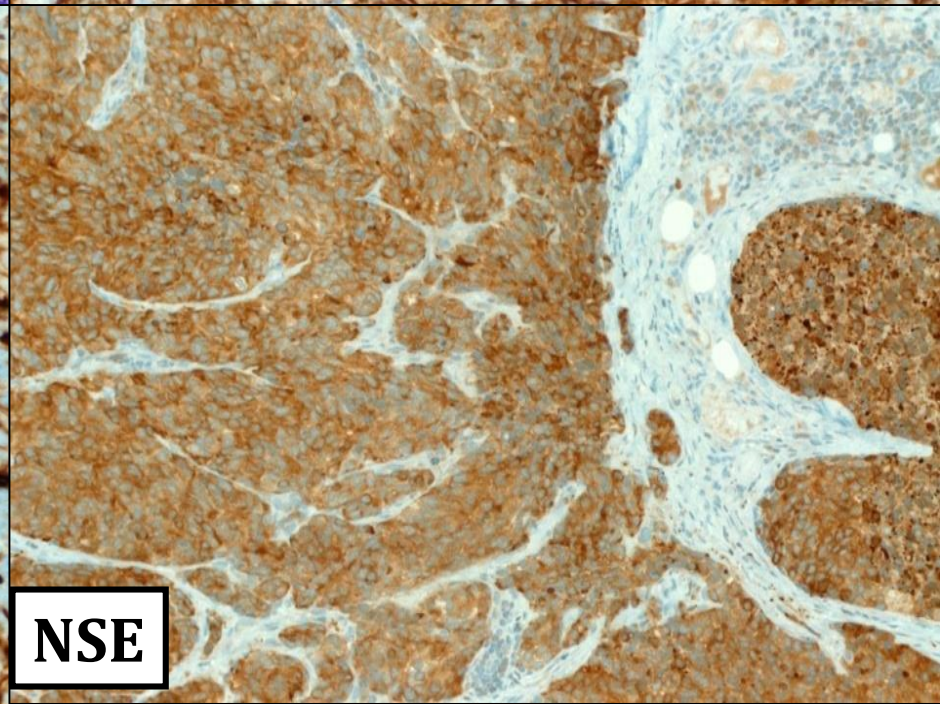
**19 yrs, male, cervical node mets referred as poorly diff carcinoma (CUP)**



**Pan-CK**



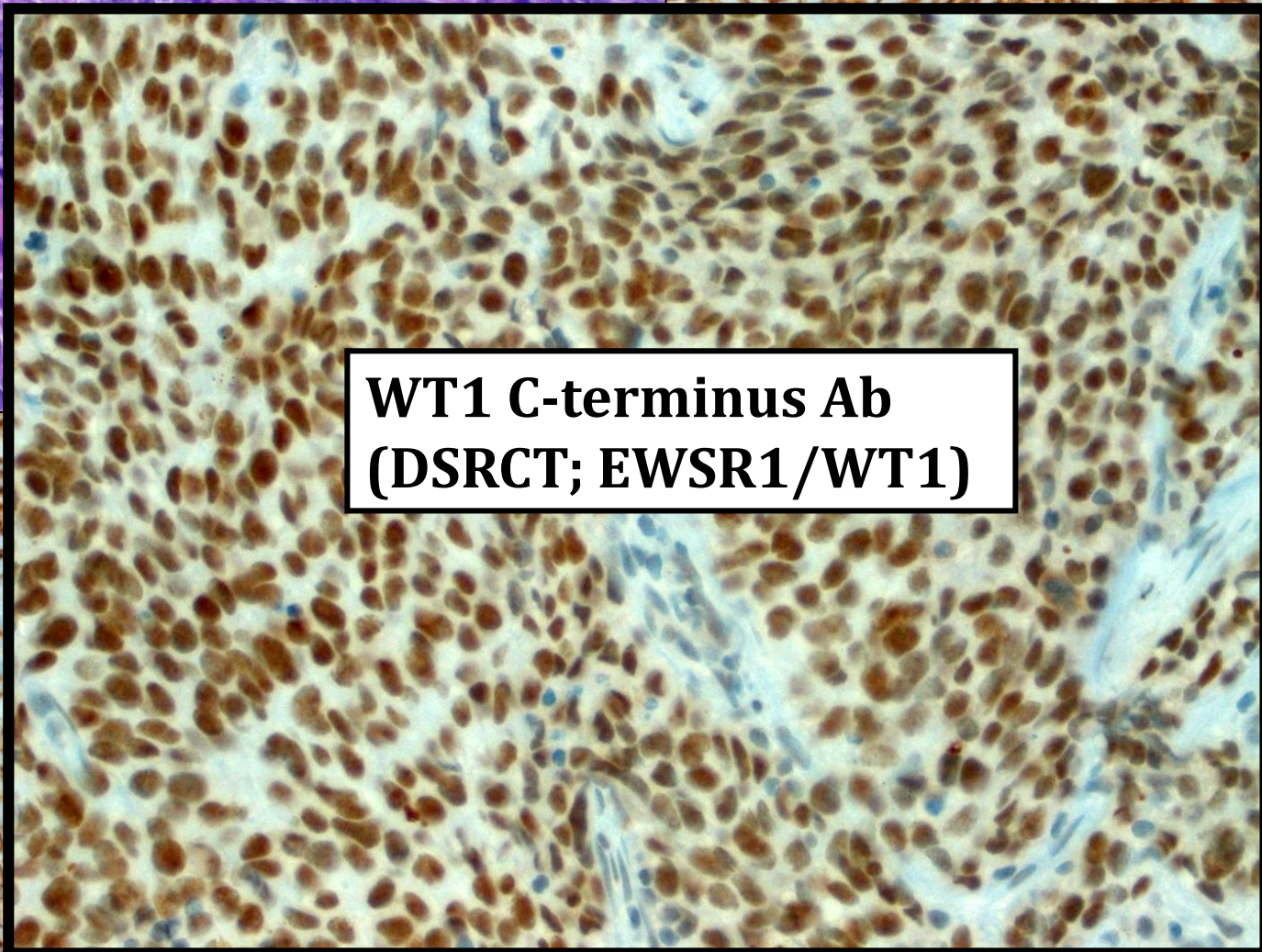
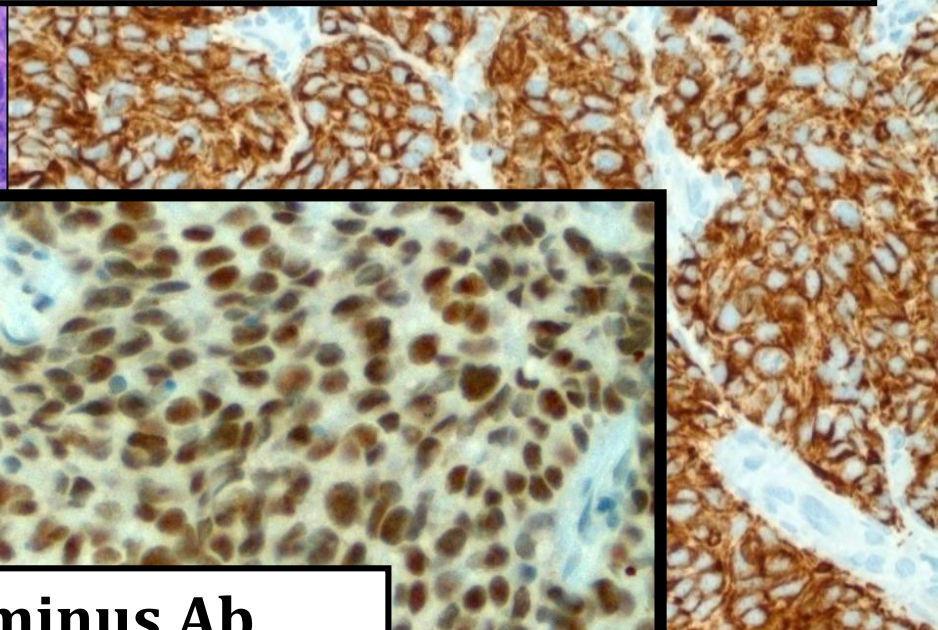
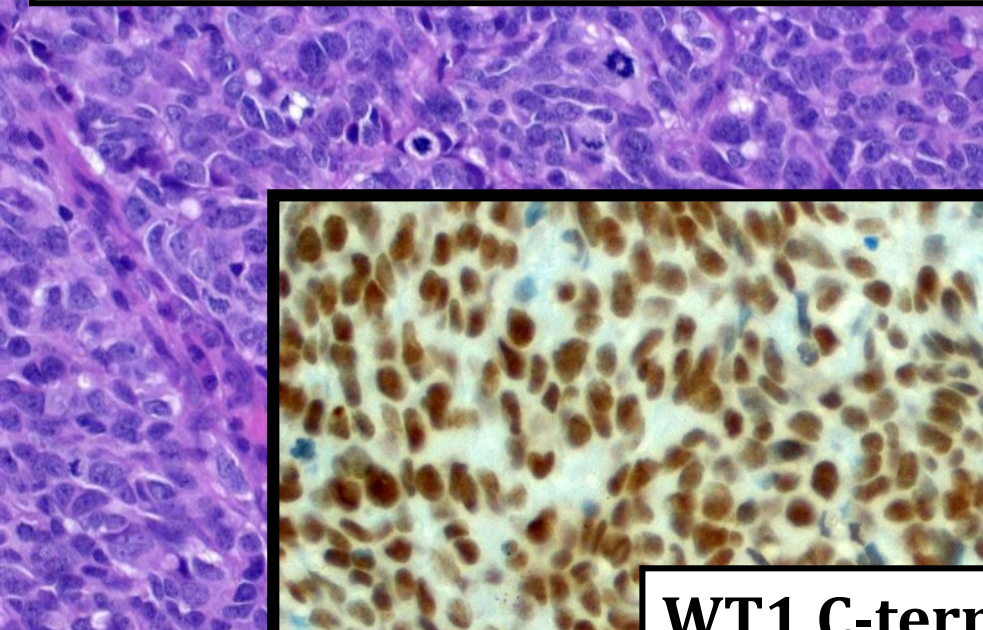
**Desmin**



**NSE**



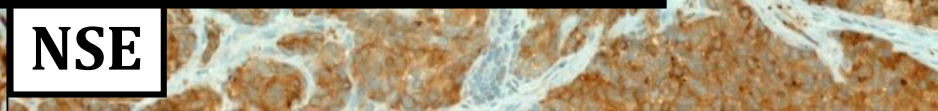
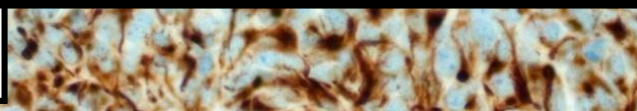19 yrs, male, cervical node mets referred as poorly diff carcinoma (CUP)



**WT1 C-terminus Ab  
(DSRCT; EWSR1/WT1)**

**Desmin**

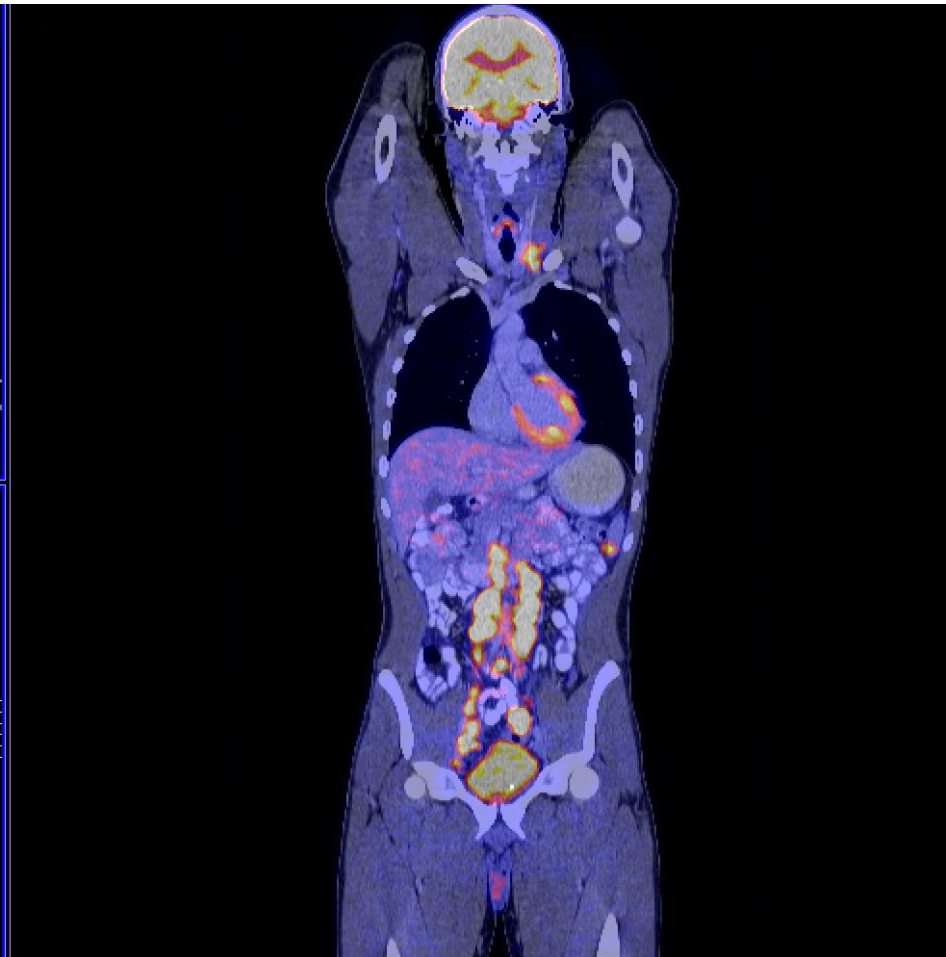
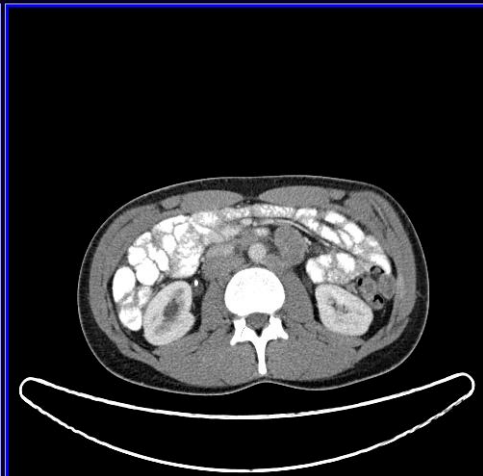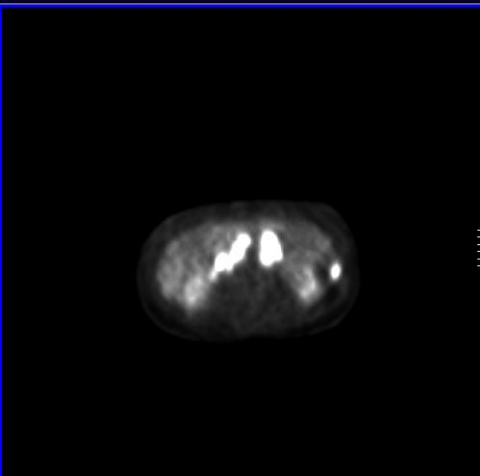
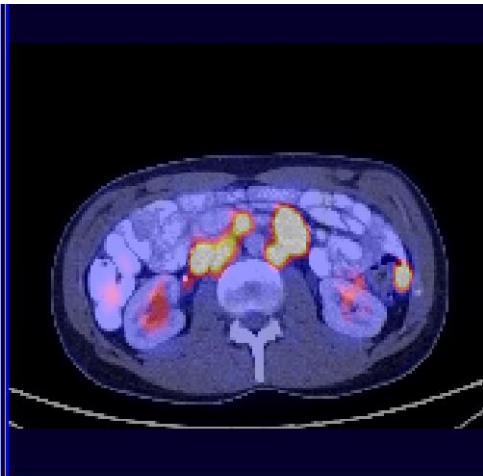
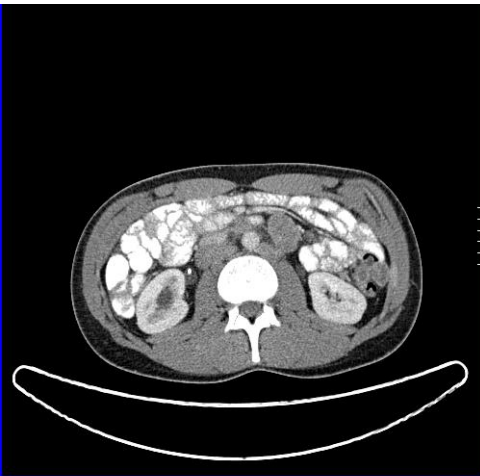
**NSE**





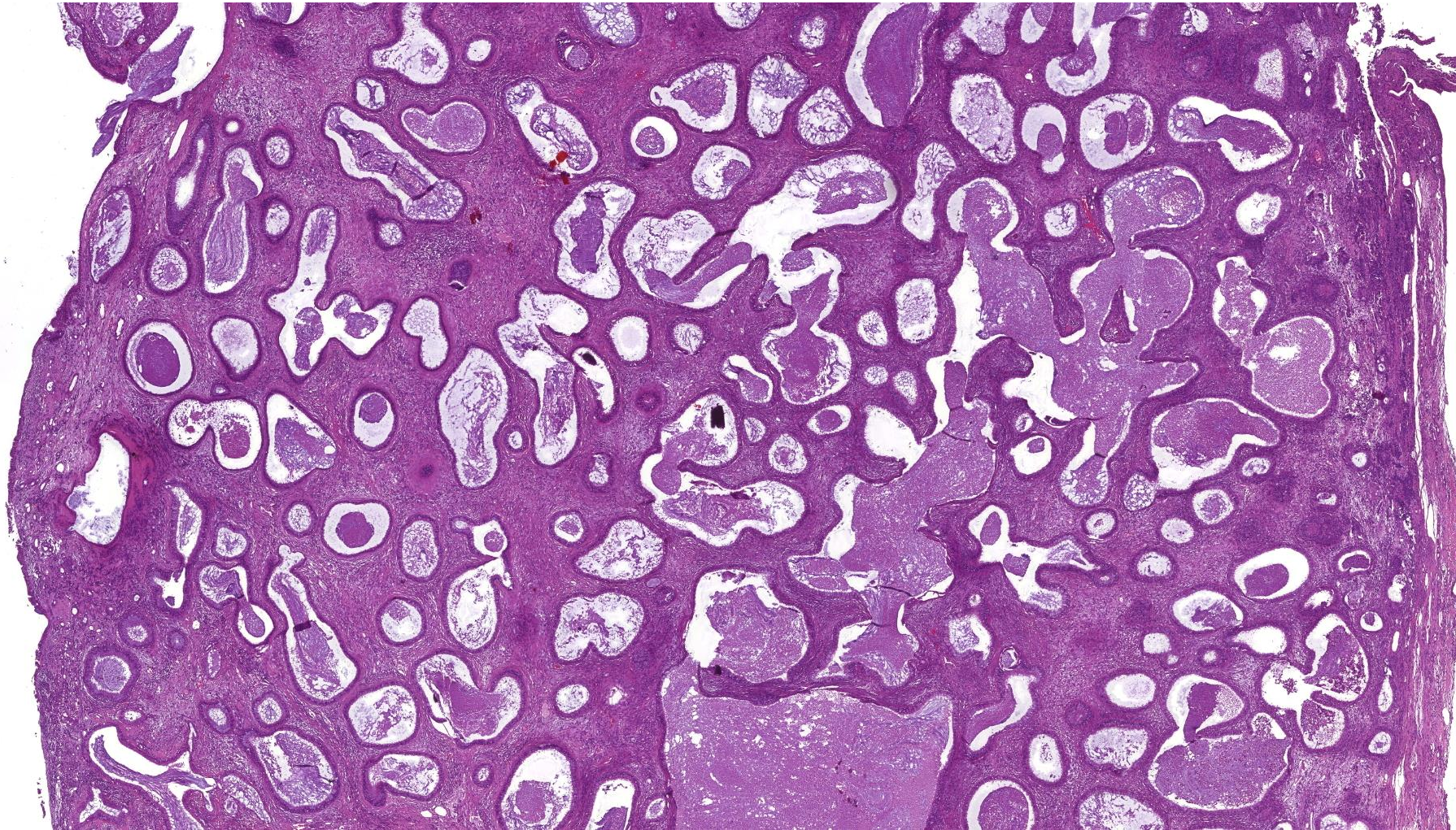
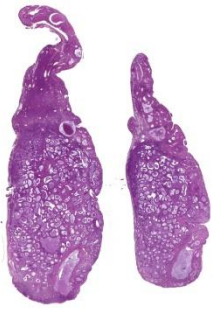

# Pt has extensive abdominopelvic disease

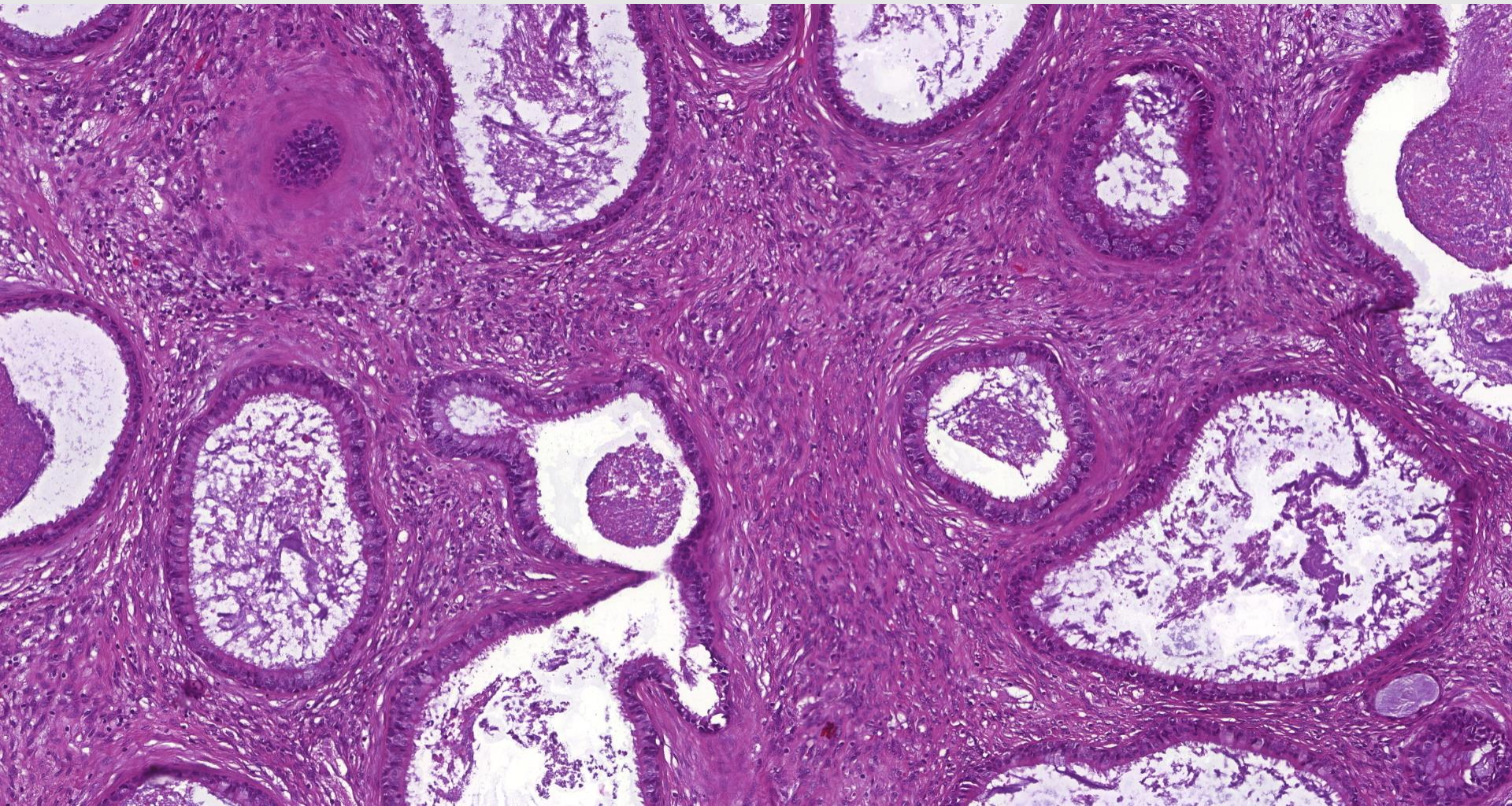




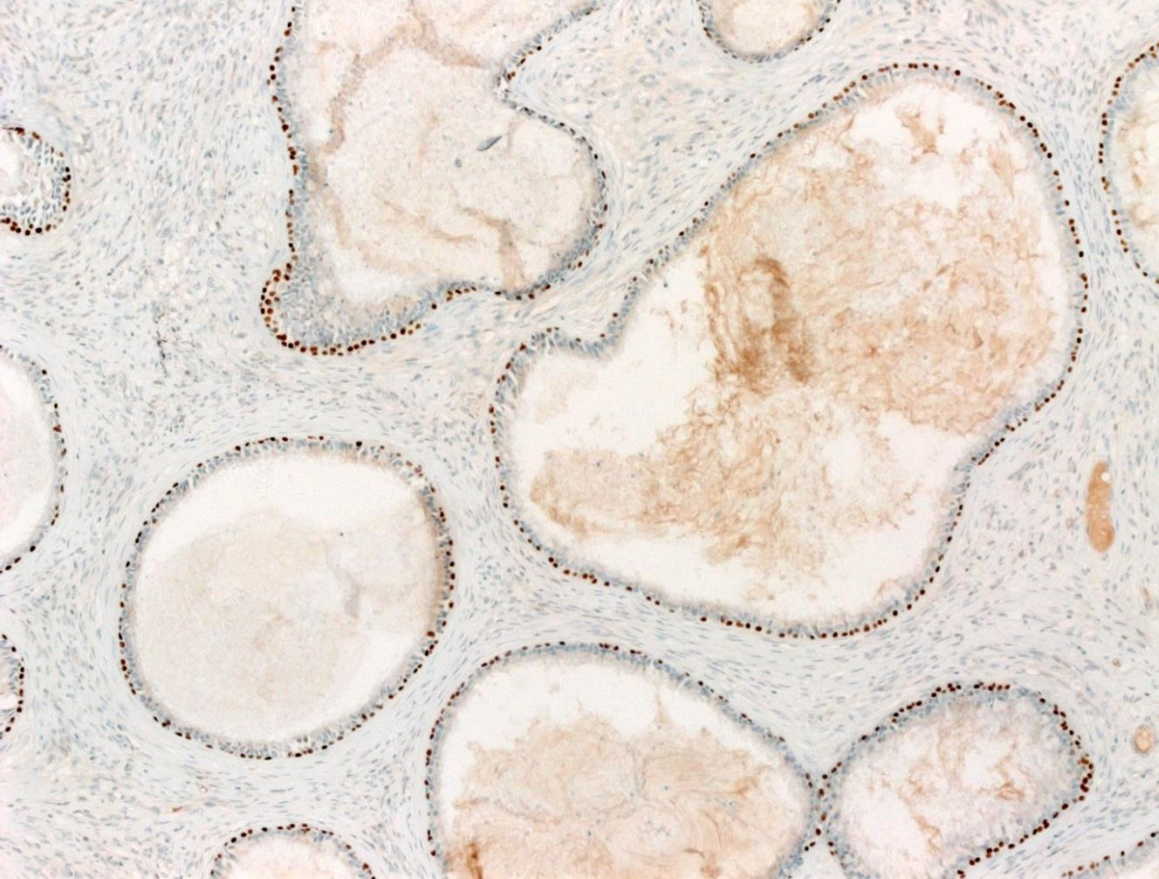**65 yo male with nasal polyp**











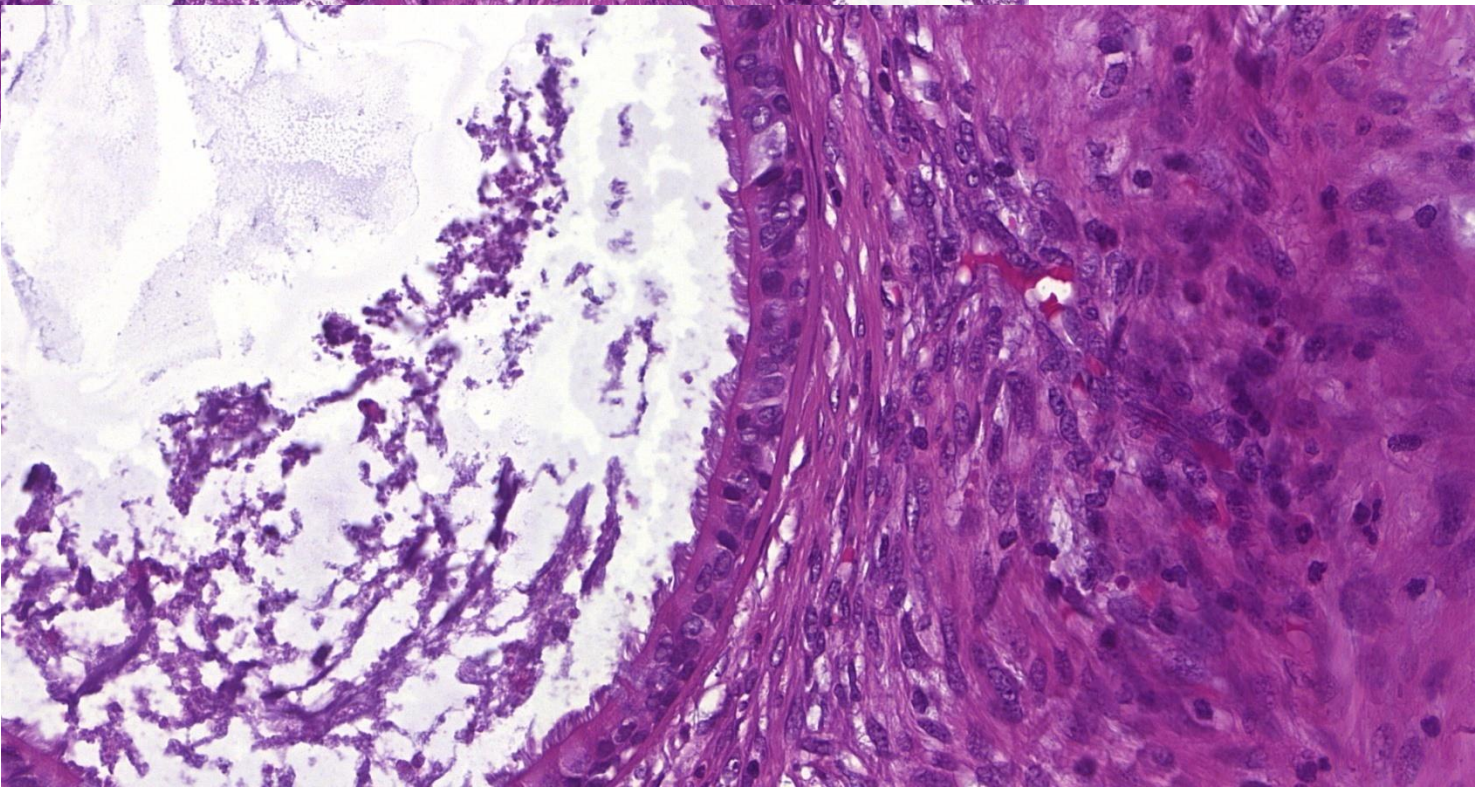
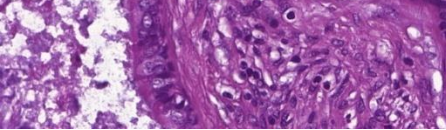
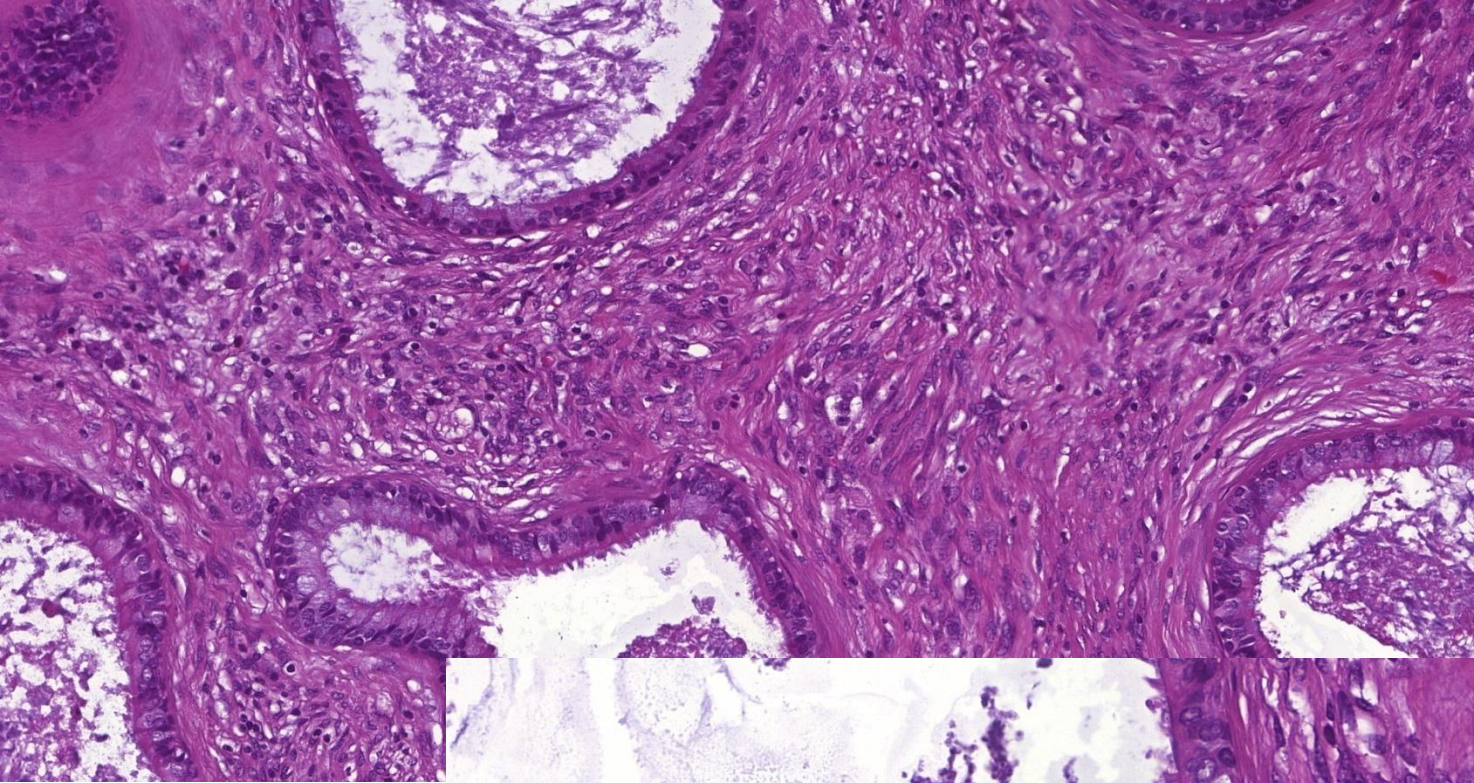
**p63**

## **DDx**

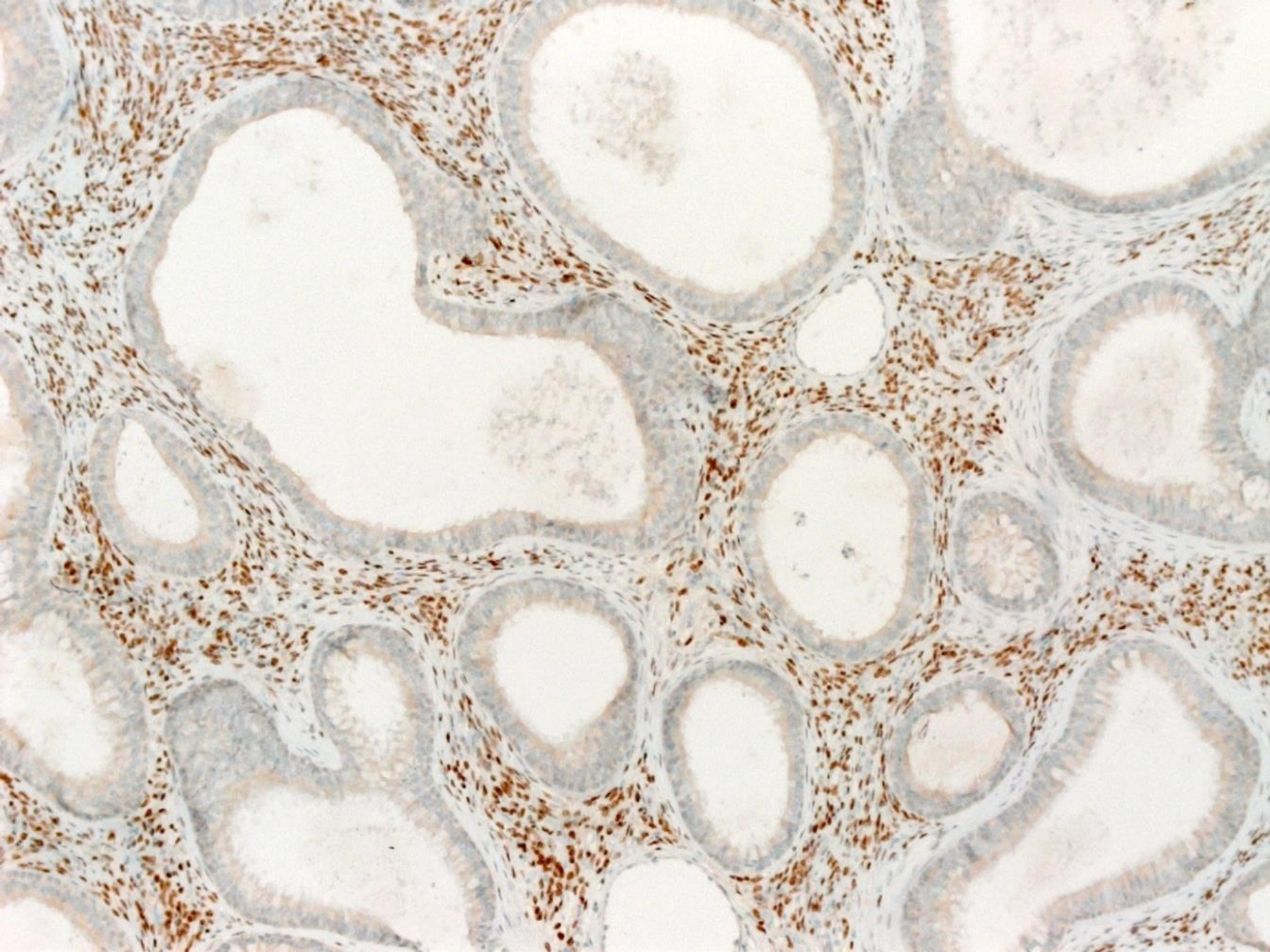
- **REAH-hamartoma**
- **Paucicellular biphenotypic sinonasal sarcoma (BSS)**
- **Something else?**













The image shows a histological section of tissue stained for STAT6. The tissue exhibits a complex, lobulated architecture with numerous glandular structures. The glands are lined by a layer of cells, and the surrounding stroma is densely populated with cells. The staining is brown, highlighting the presence of STAT6 in the nuclei of many cells. The overall appearance is characteristic of a sinonasal lesion, such as a solitary fibrous tumor (SFT), which often contains entrapped glands.

**STAT6**

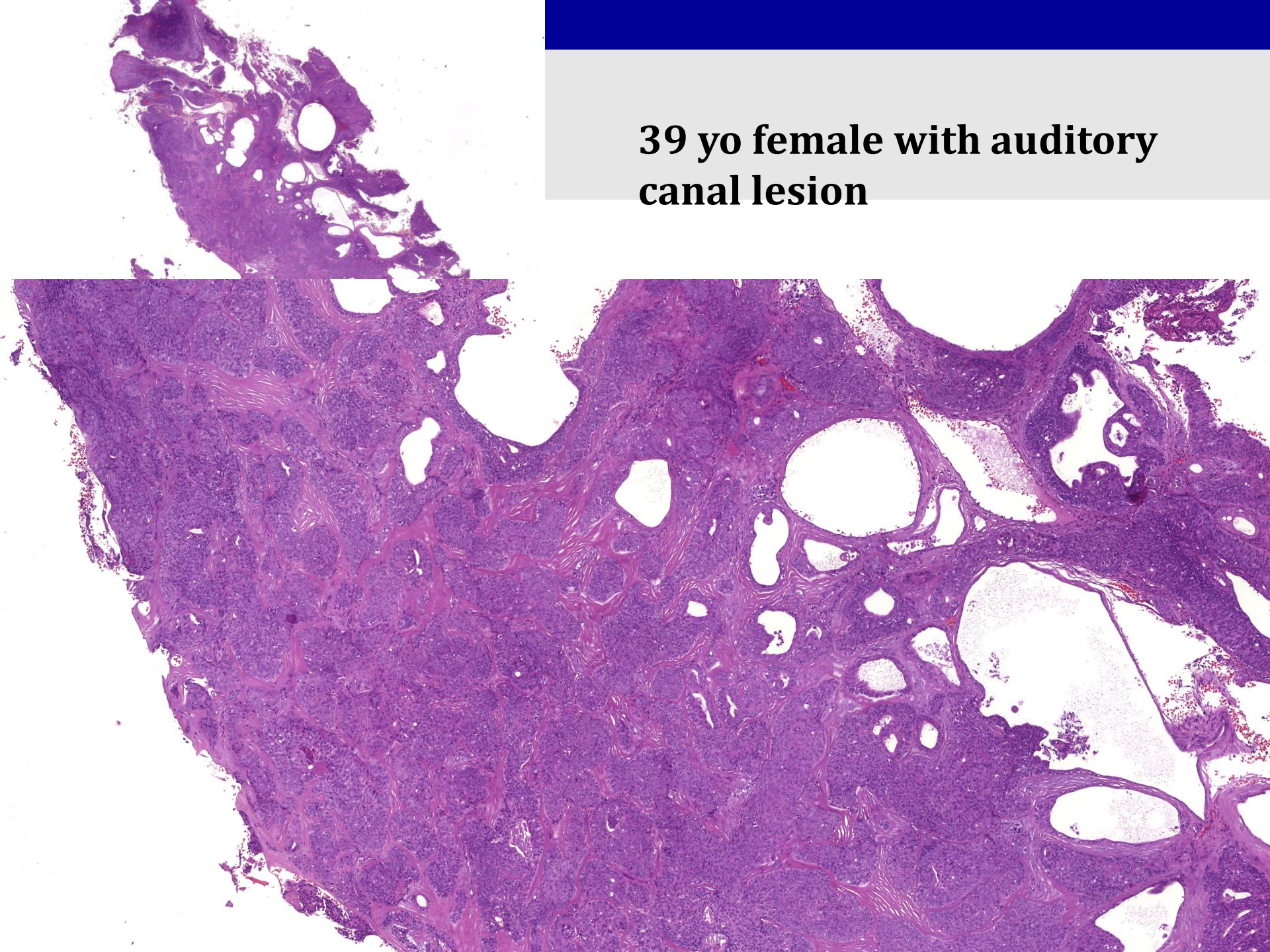
**A subset of sinonasal (and other rare head & neck)  
SFT contain prominent hamartoma-like entrapped glands**



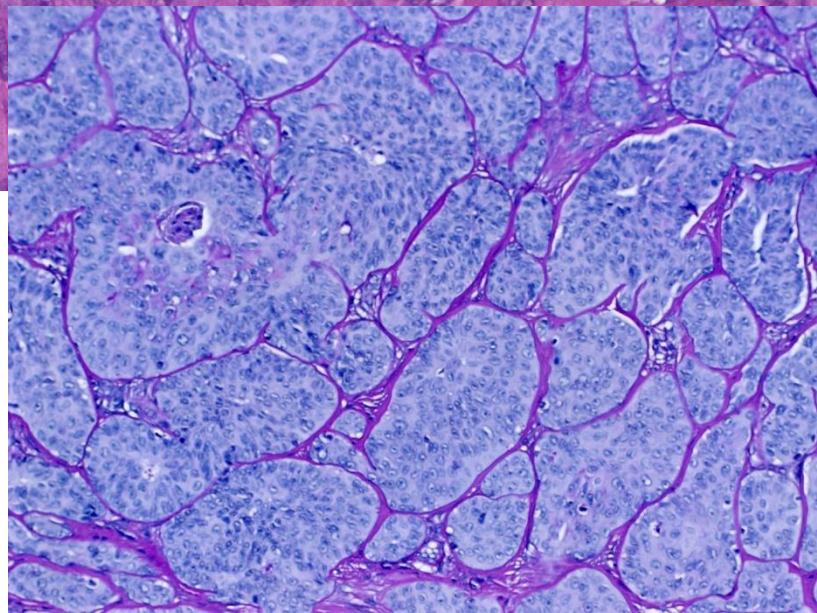
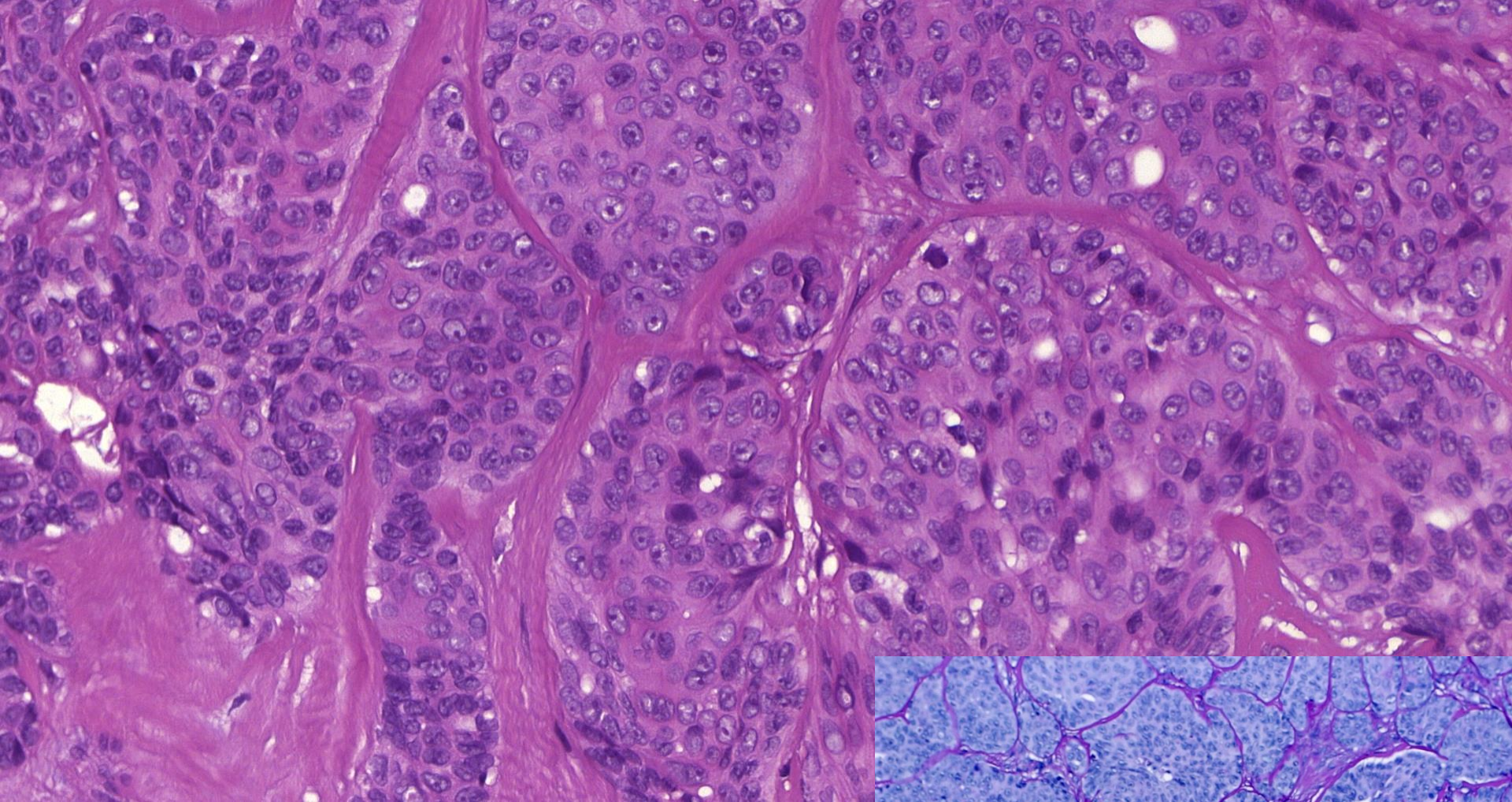




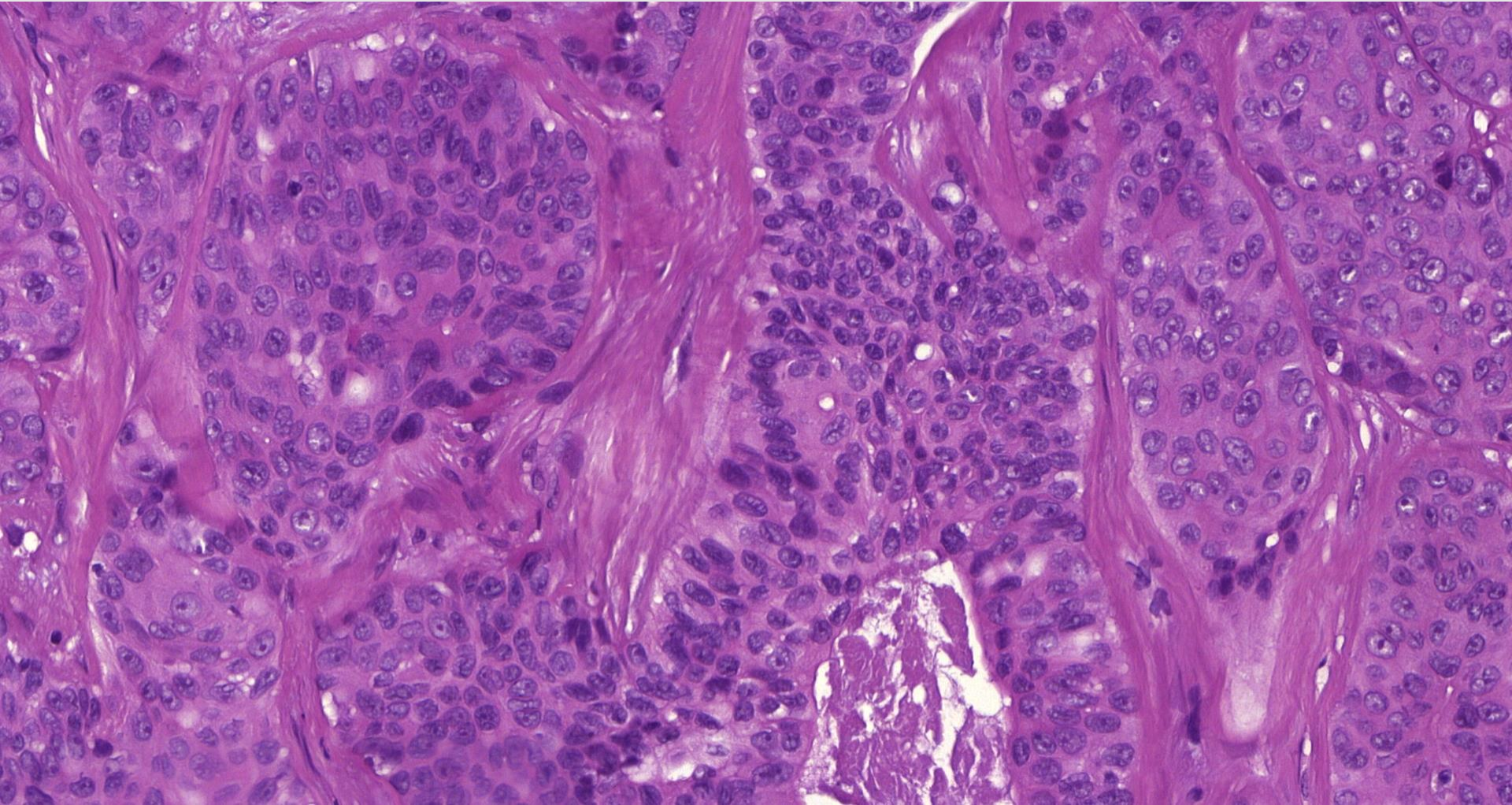
**39 yo female with auditory canal lesion**



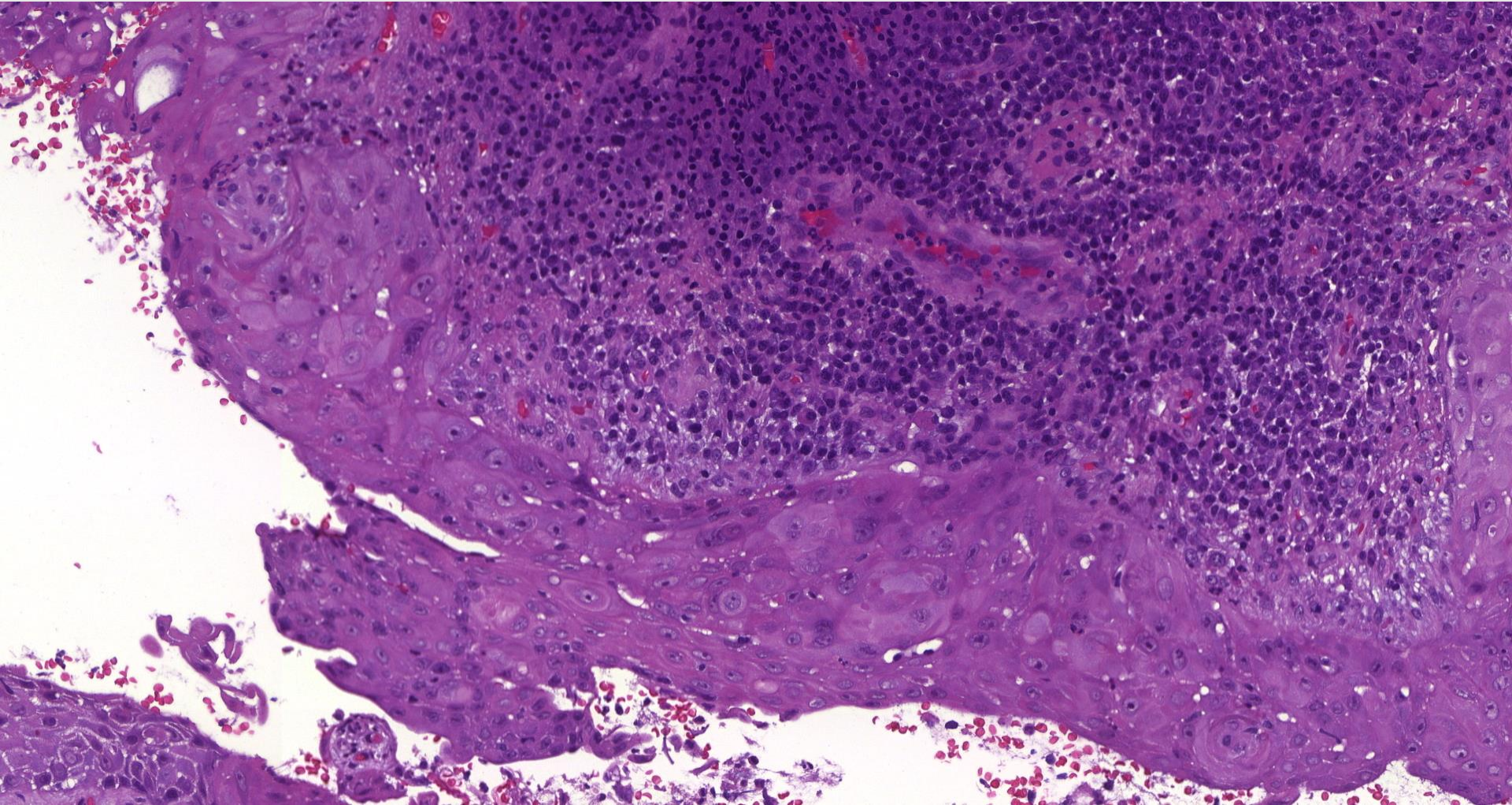






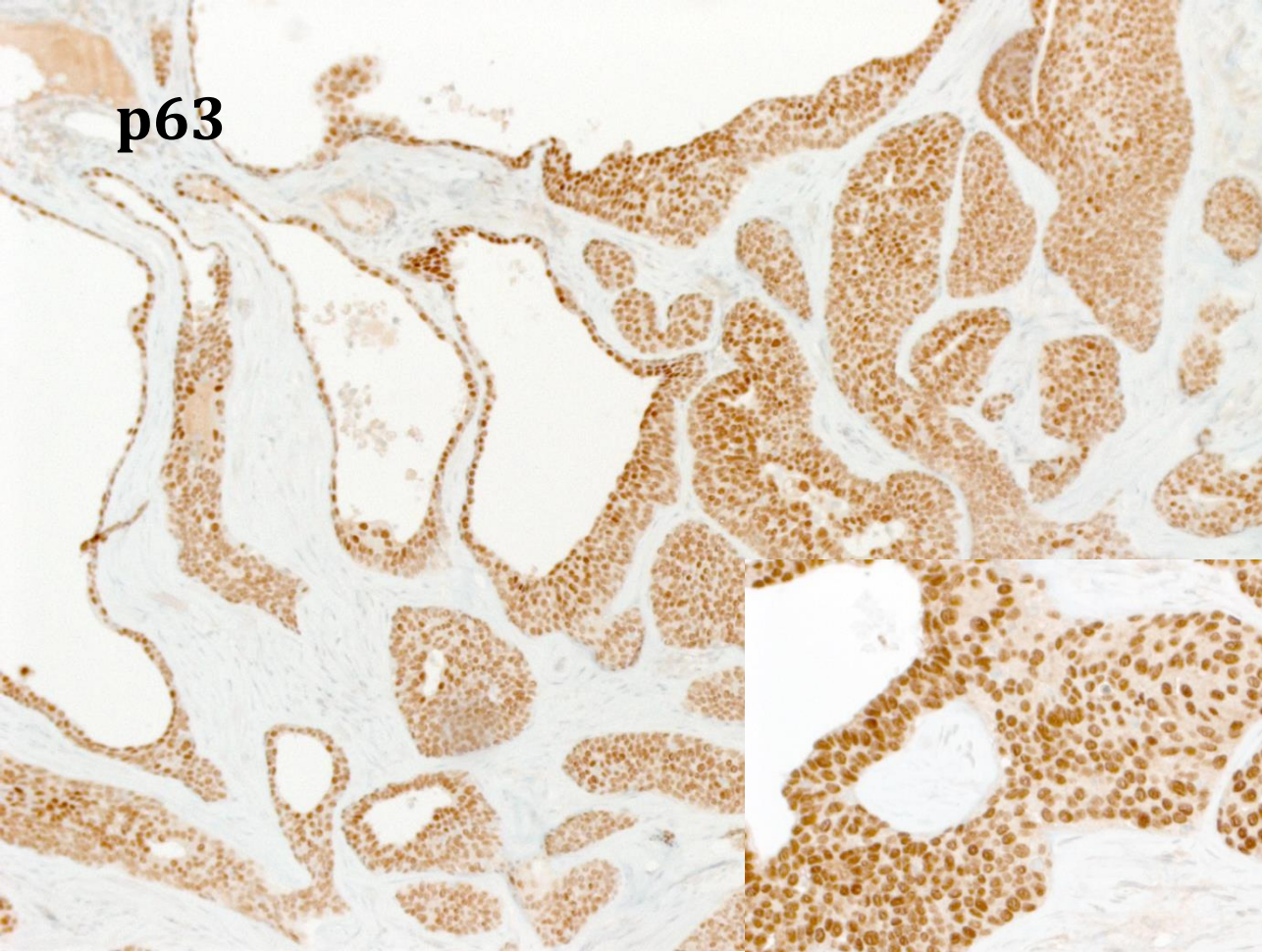




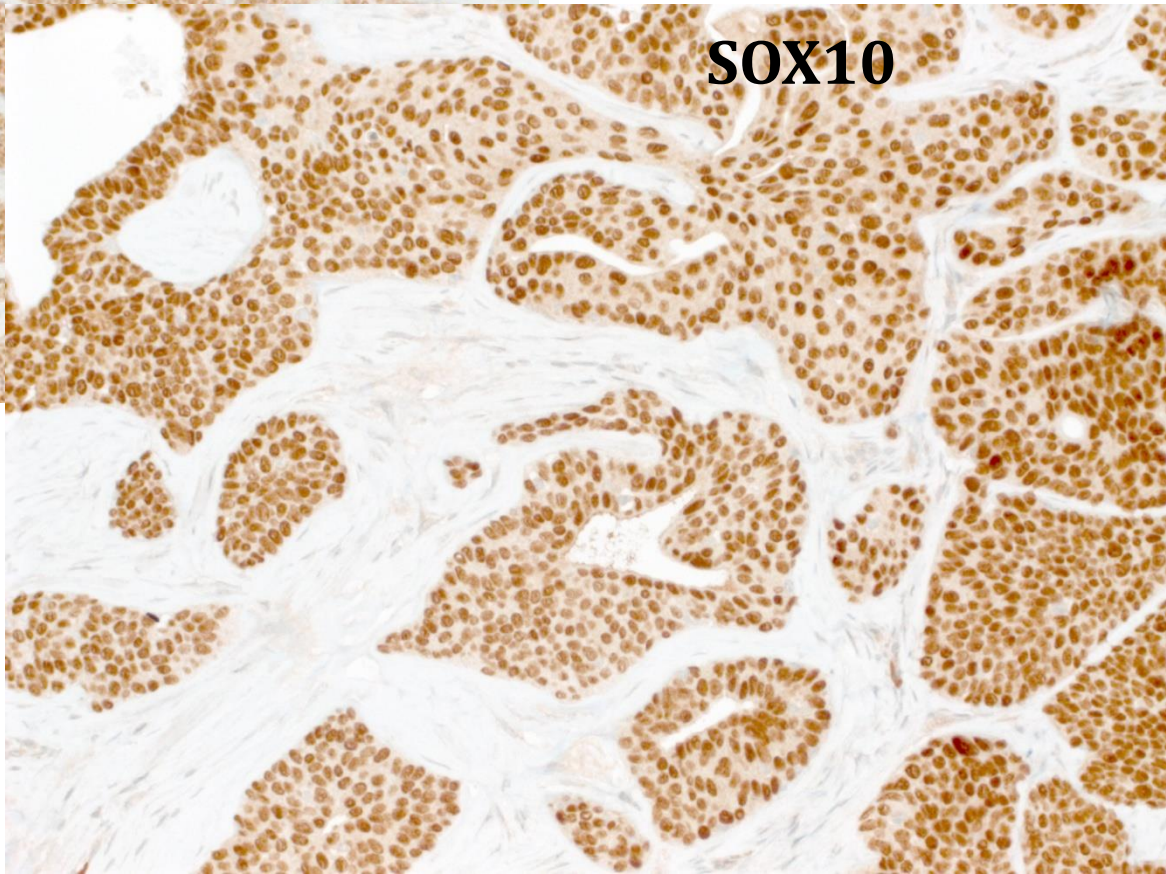




**p63**

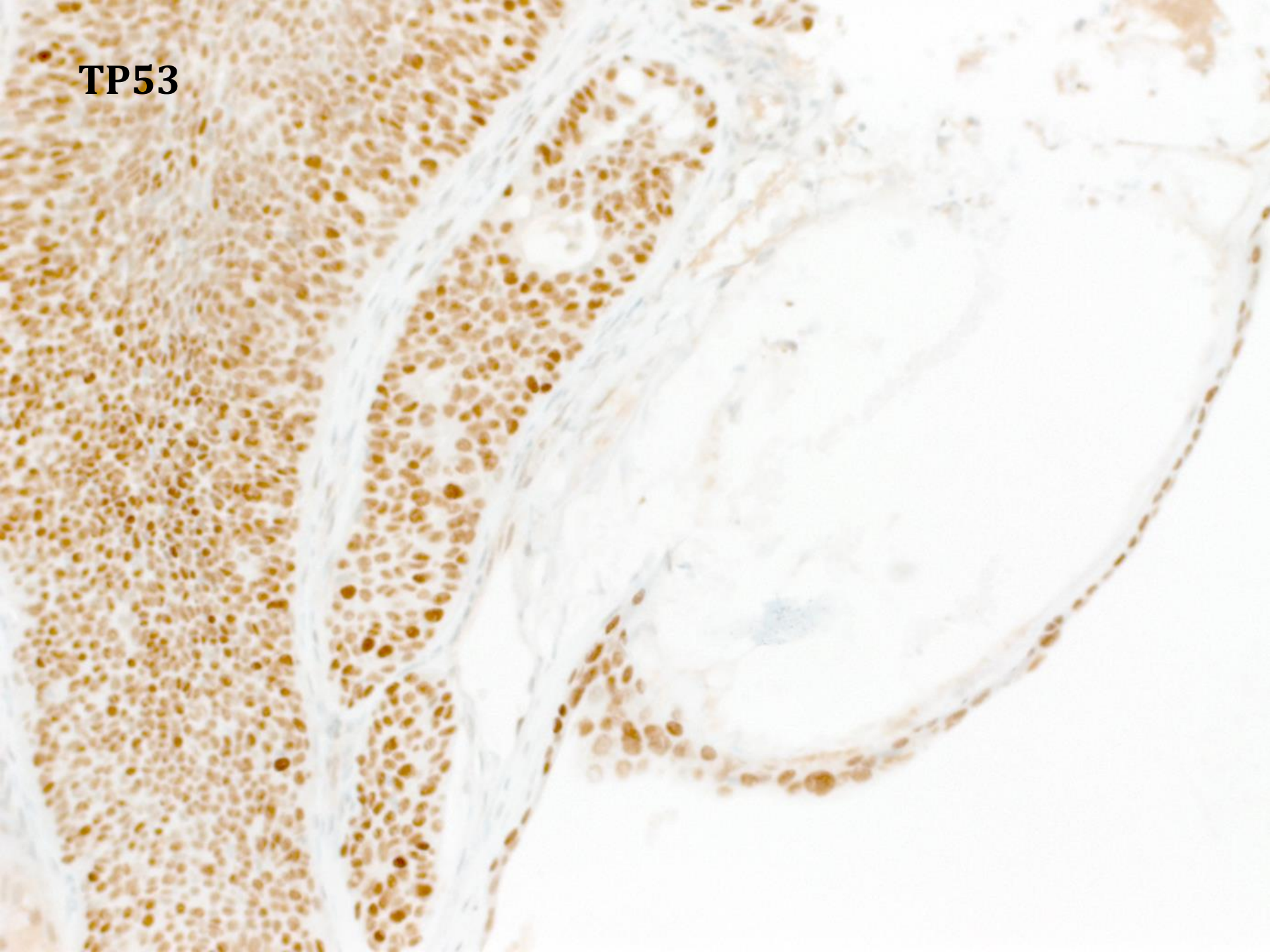


**SOX10**



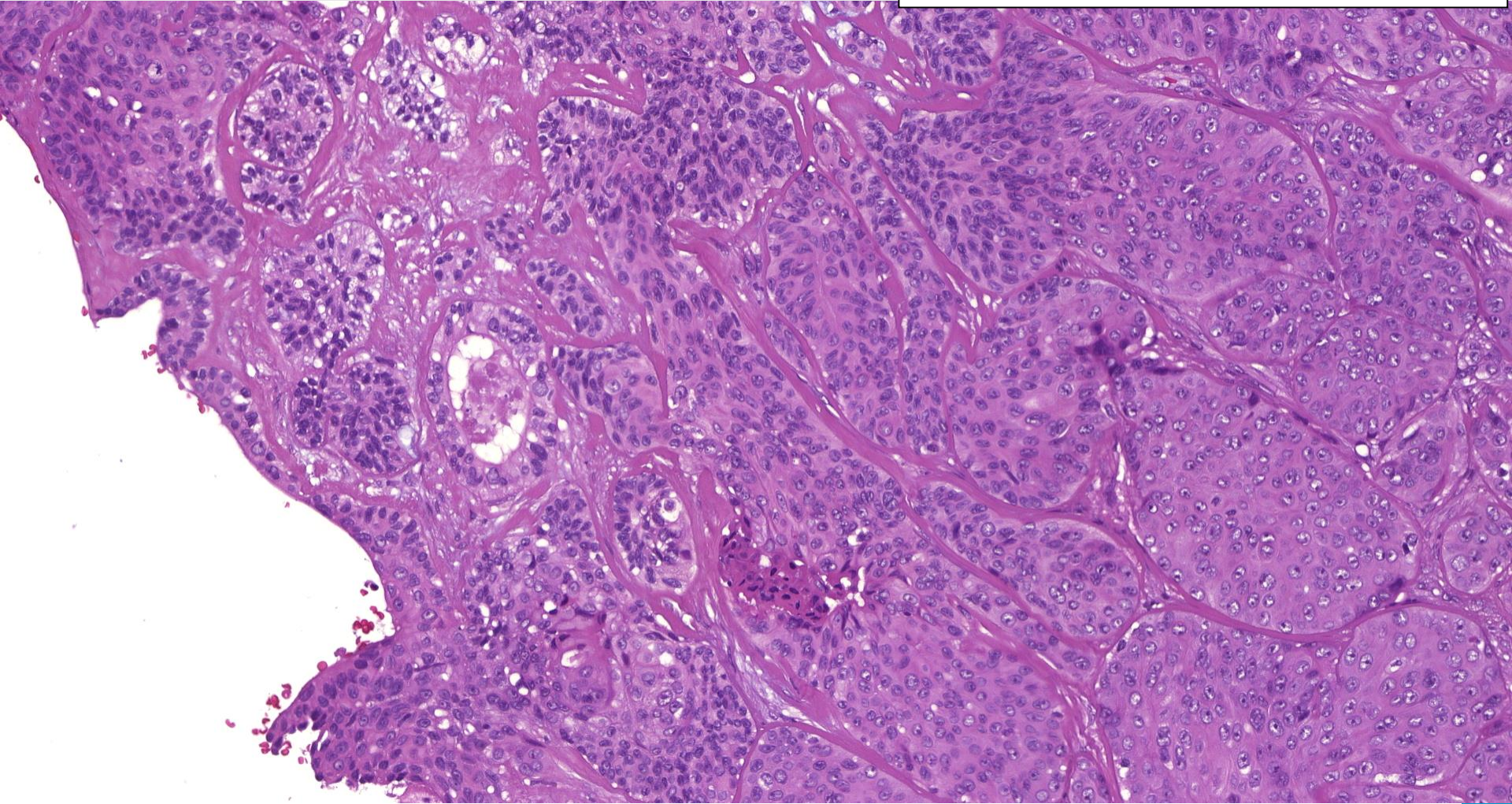


**TP53**





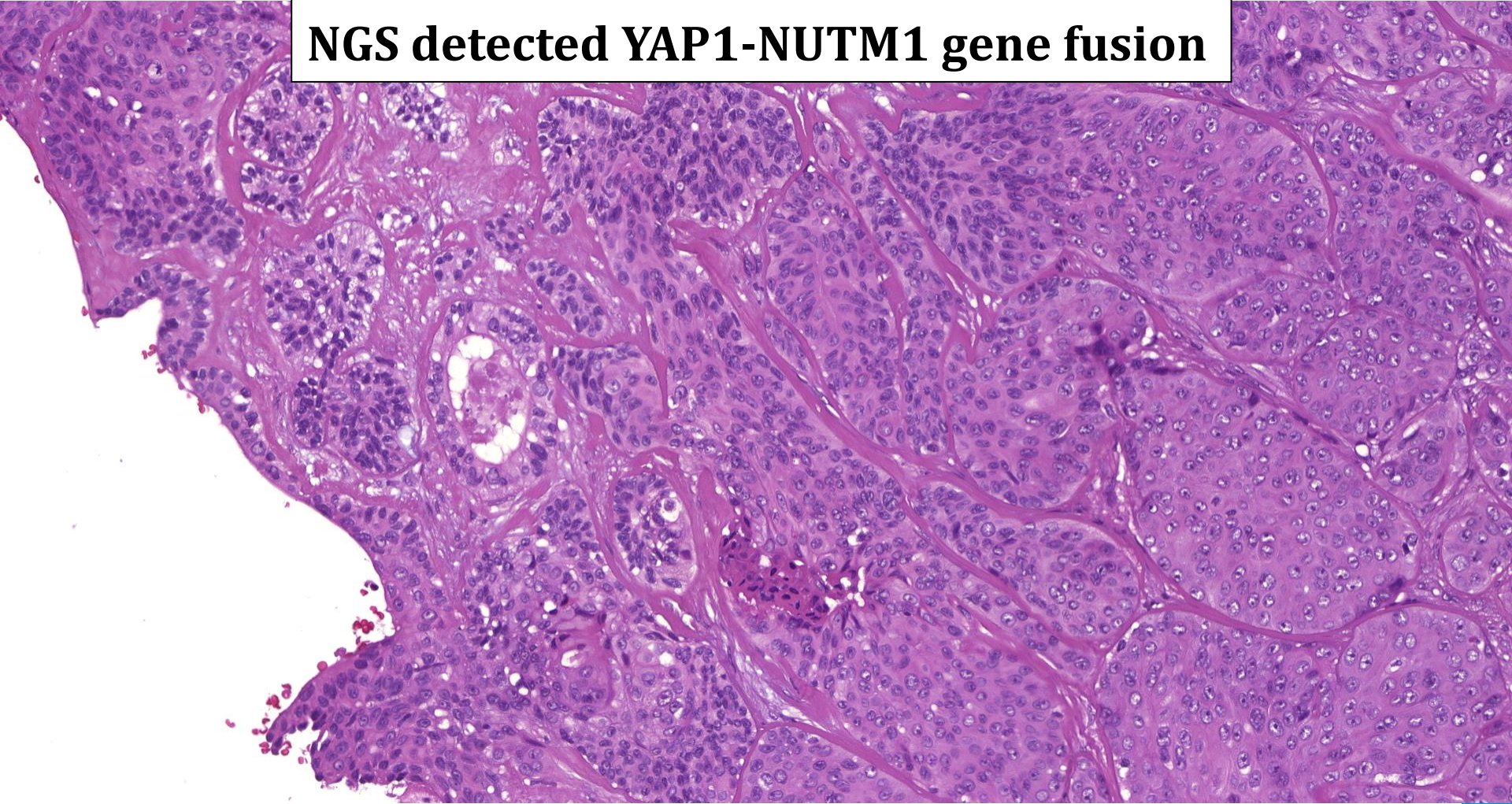
**Skin adnexal carcinoma?  
Ceruminous carcinoma?**





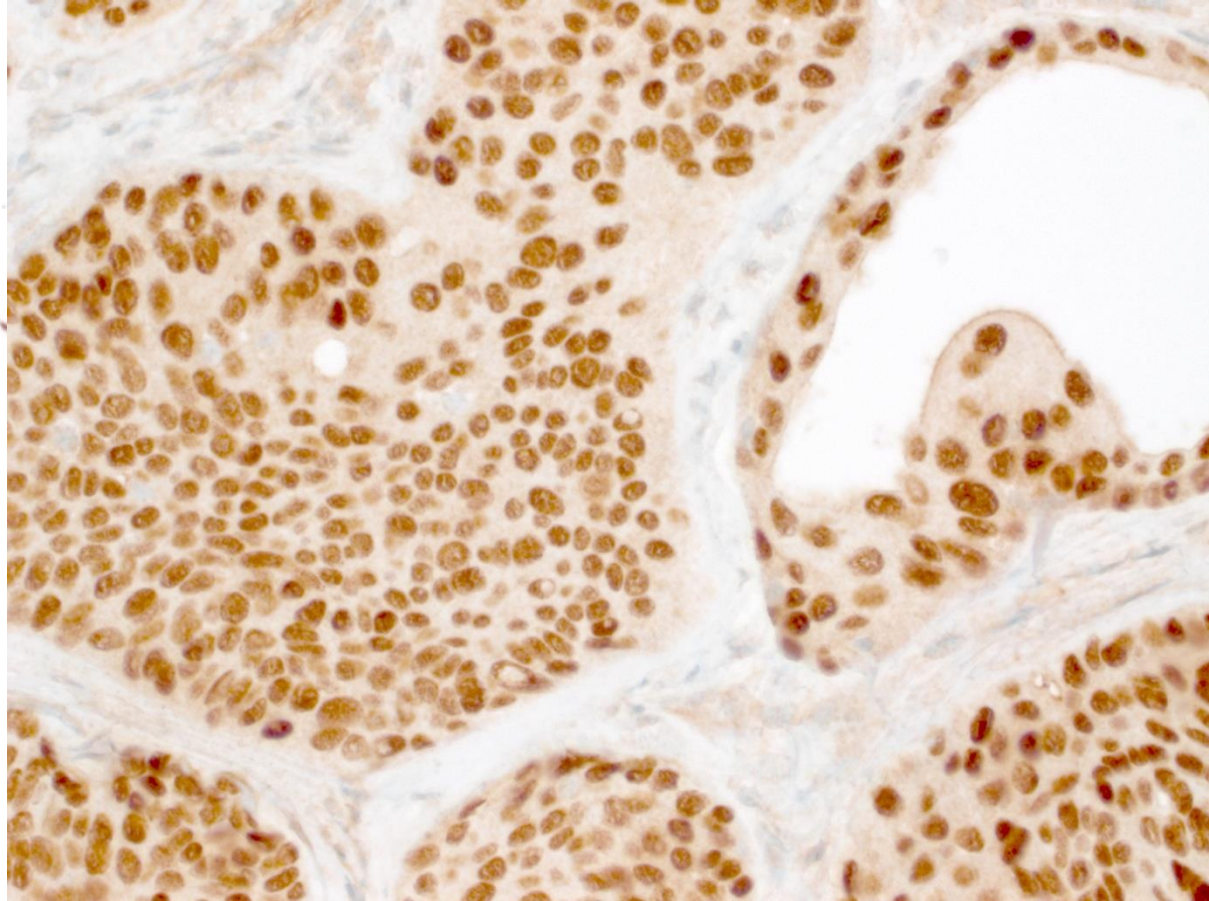
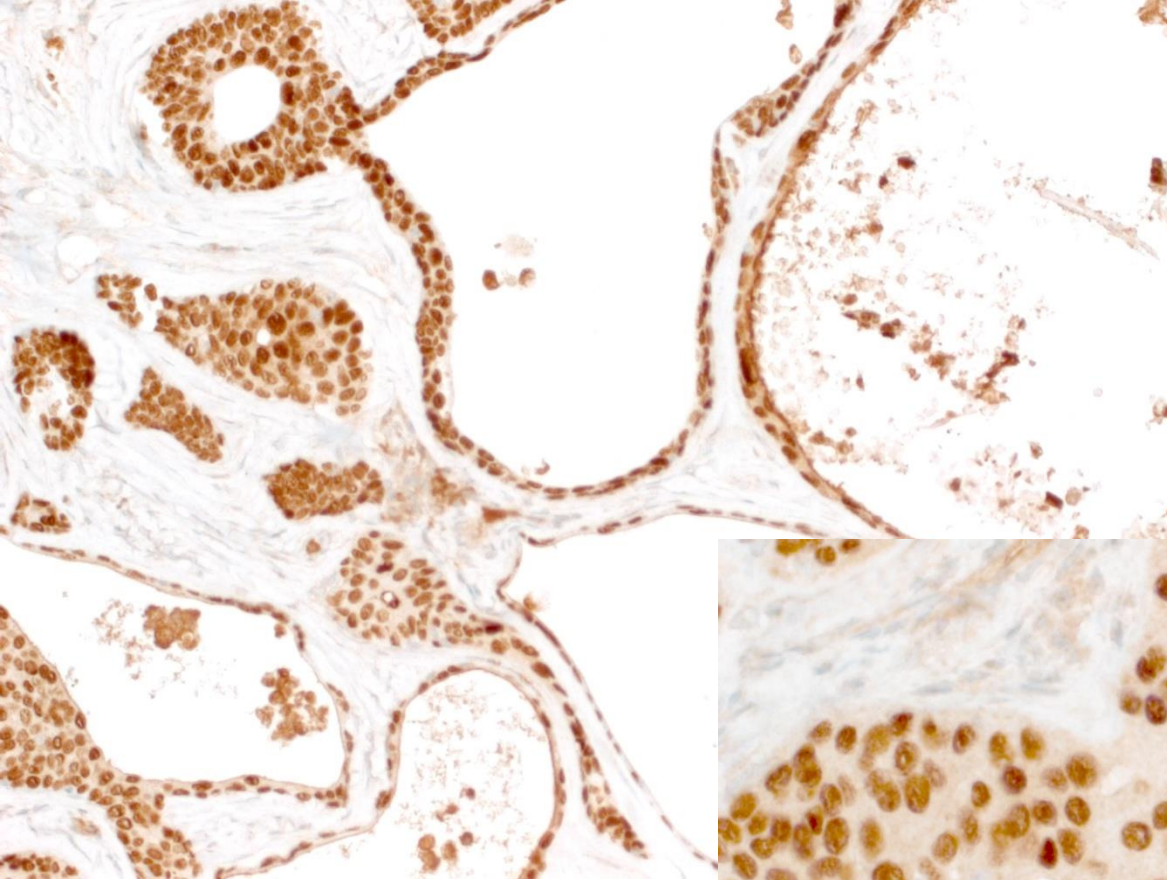
**Skin adnexal carcinoma?  
Ceruminous carcinoma?**

**NGS detected YAP1-NUTM1 gene fusion**



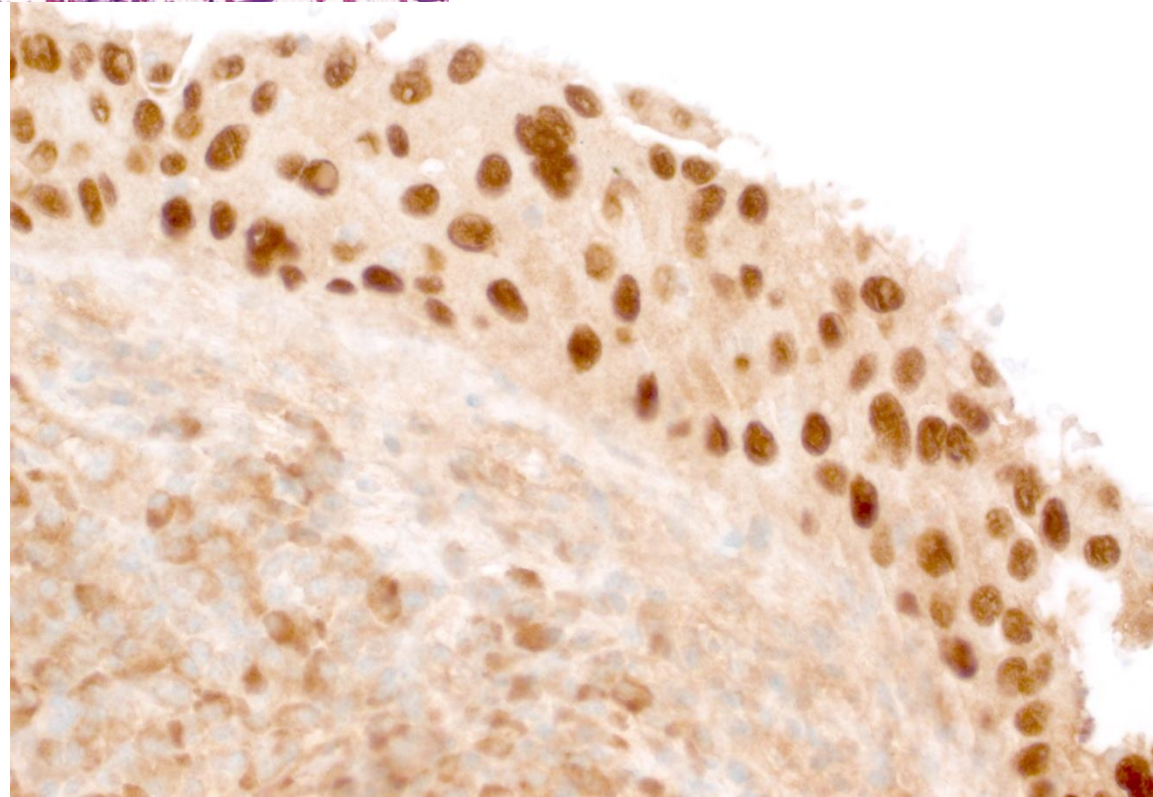
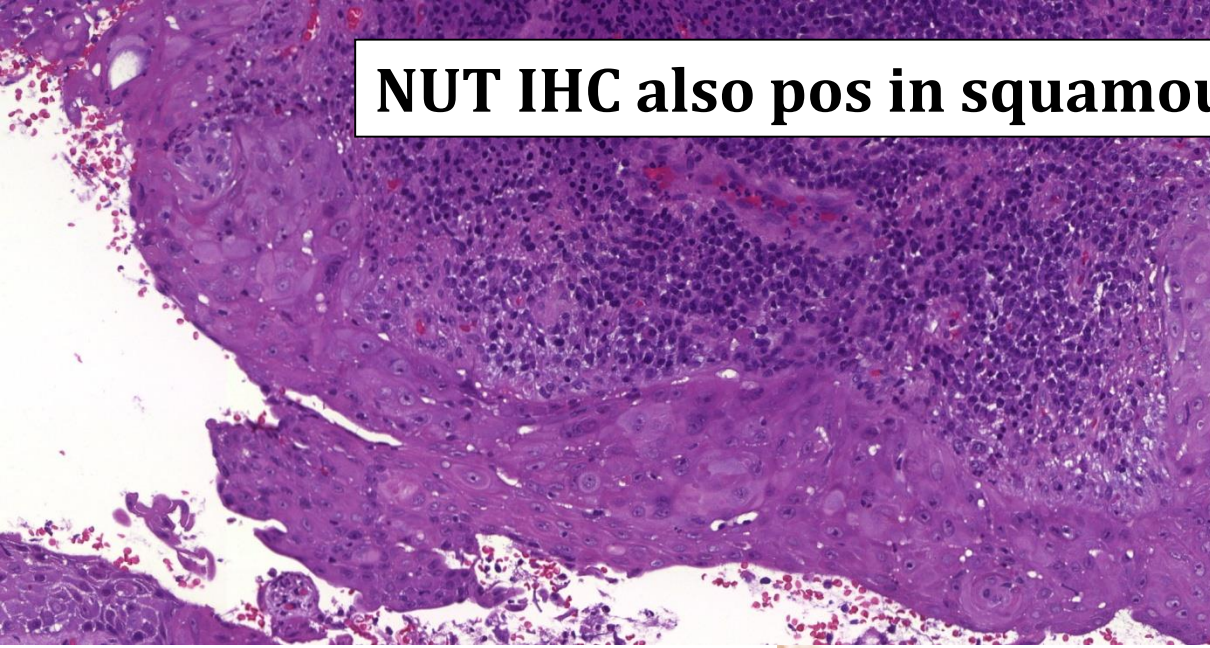


# NUT IHC





**NUT IHC also pos in squamous surface component**





## Recurrent *YAP1-MAML2* and *YAP1-NUTM1* fusions in poroma and porocarcinoma

Shigeki Sekine, ... , Naoya Yamazaki, Taisuke Mori

*J Clin Invest.* 2019. <https://doi.org/10.1172/JCI126185>.

**YAP1-MAML2 & rarely YAP1-WWTR1 & NUTM1 in >88% of poromas and 63% of porocarcinoma.**

**Porocarcinoma mainly showed YAP1-NUTM1 fusions.**

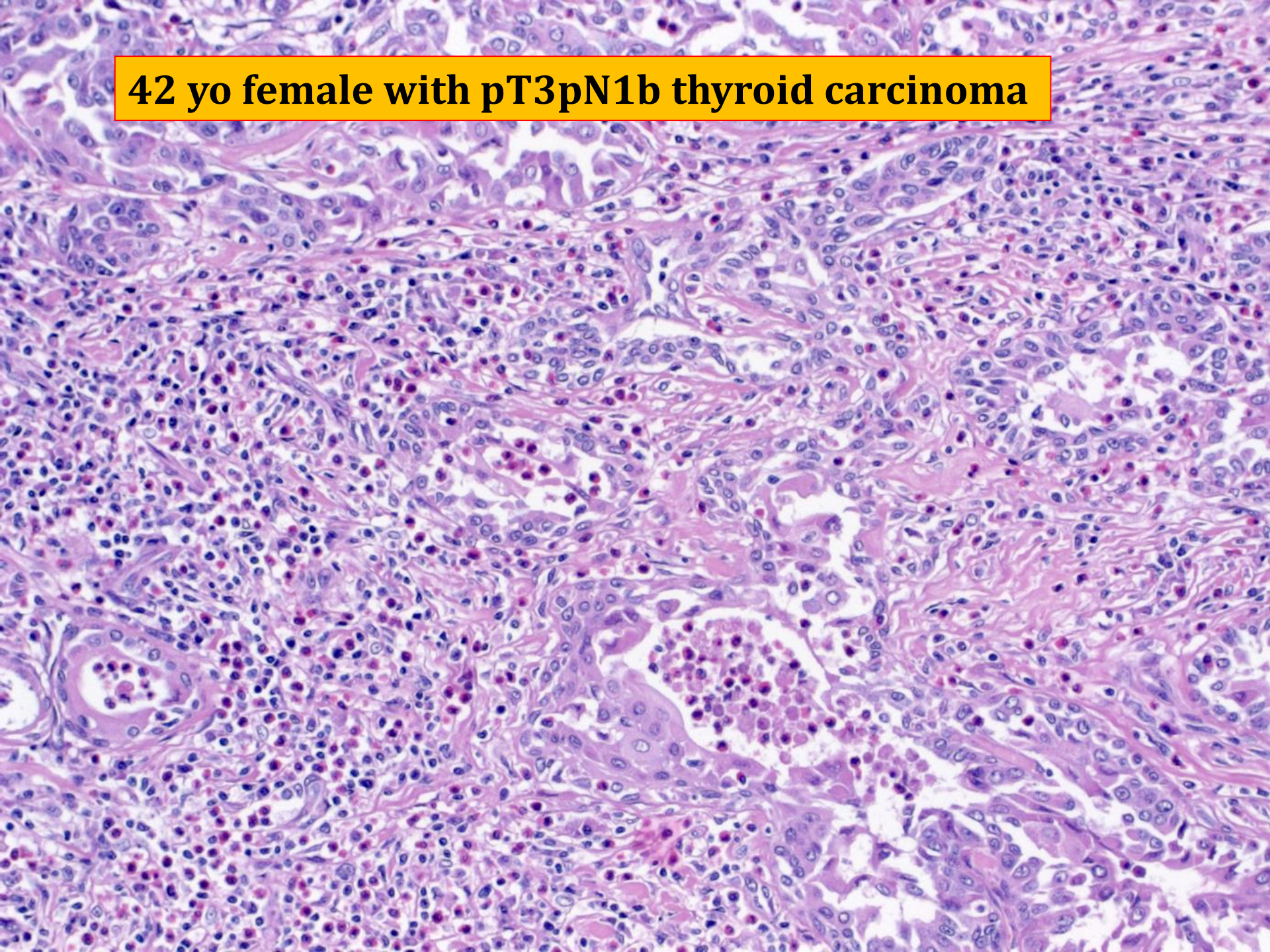
**This case likely represents unusual location of porocarcinoma with YAP1-NUTM1 fusion**



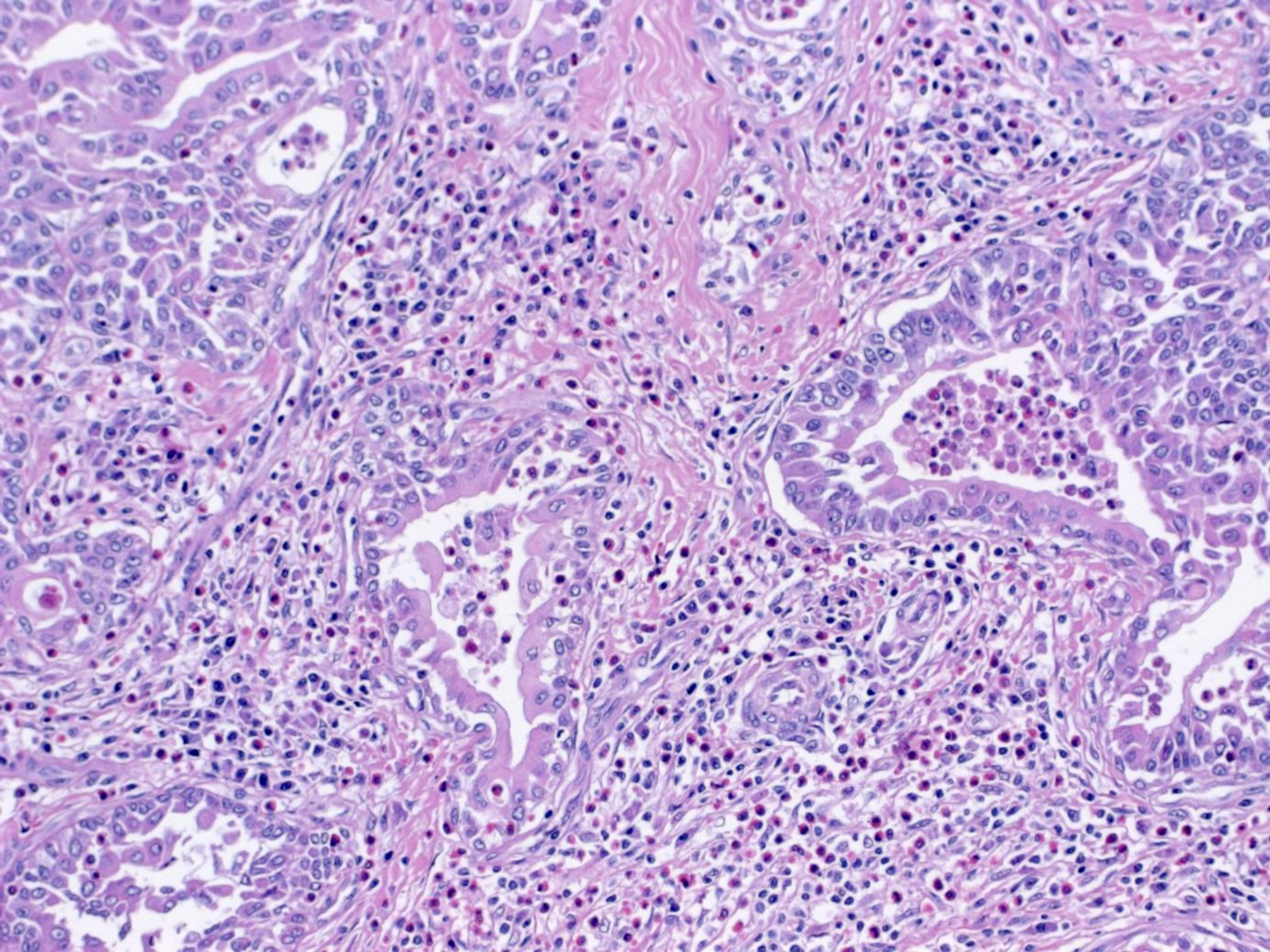




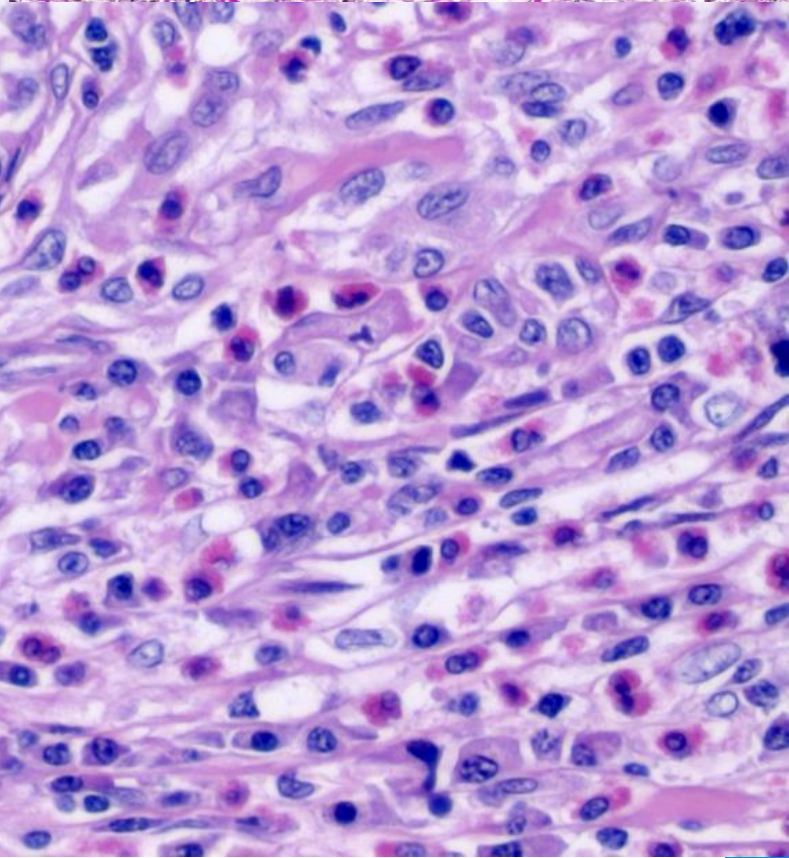
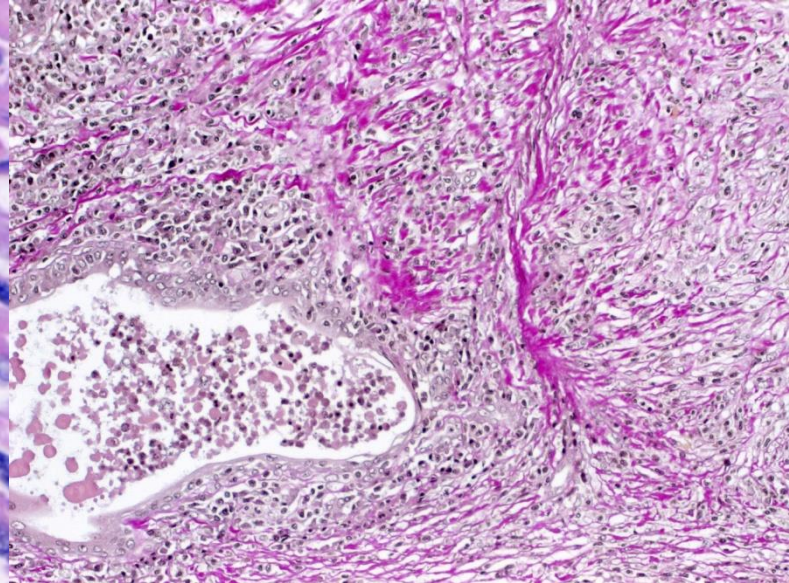
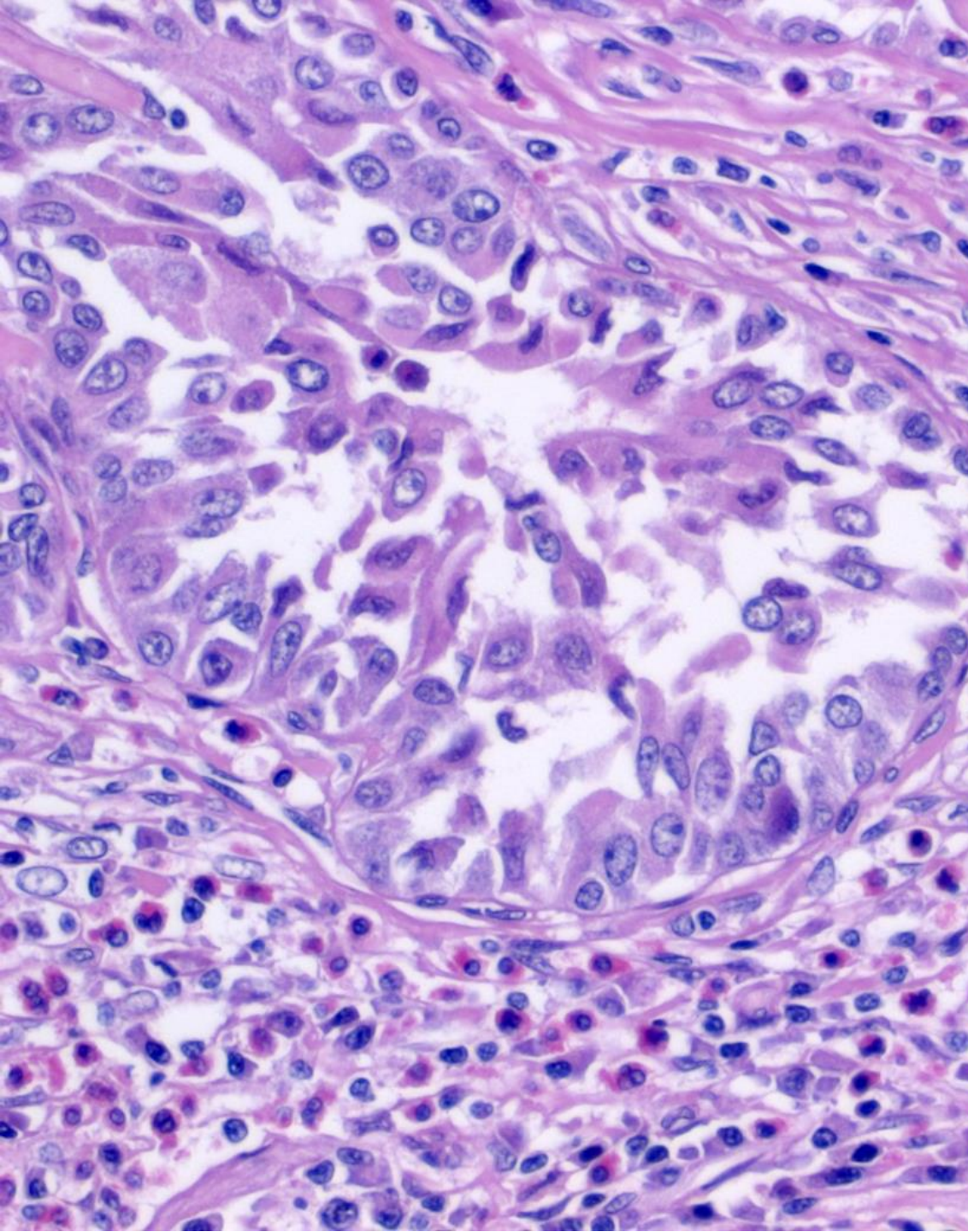
**42 yo female with pT3pN1b thyroid carcinoma**





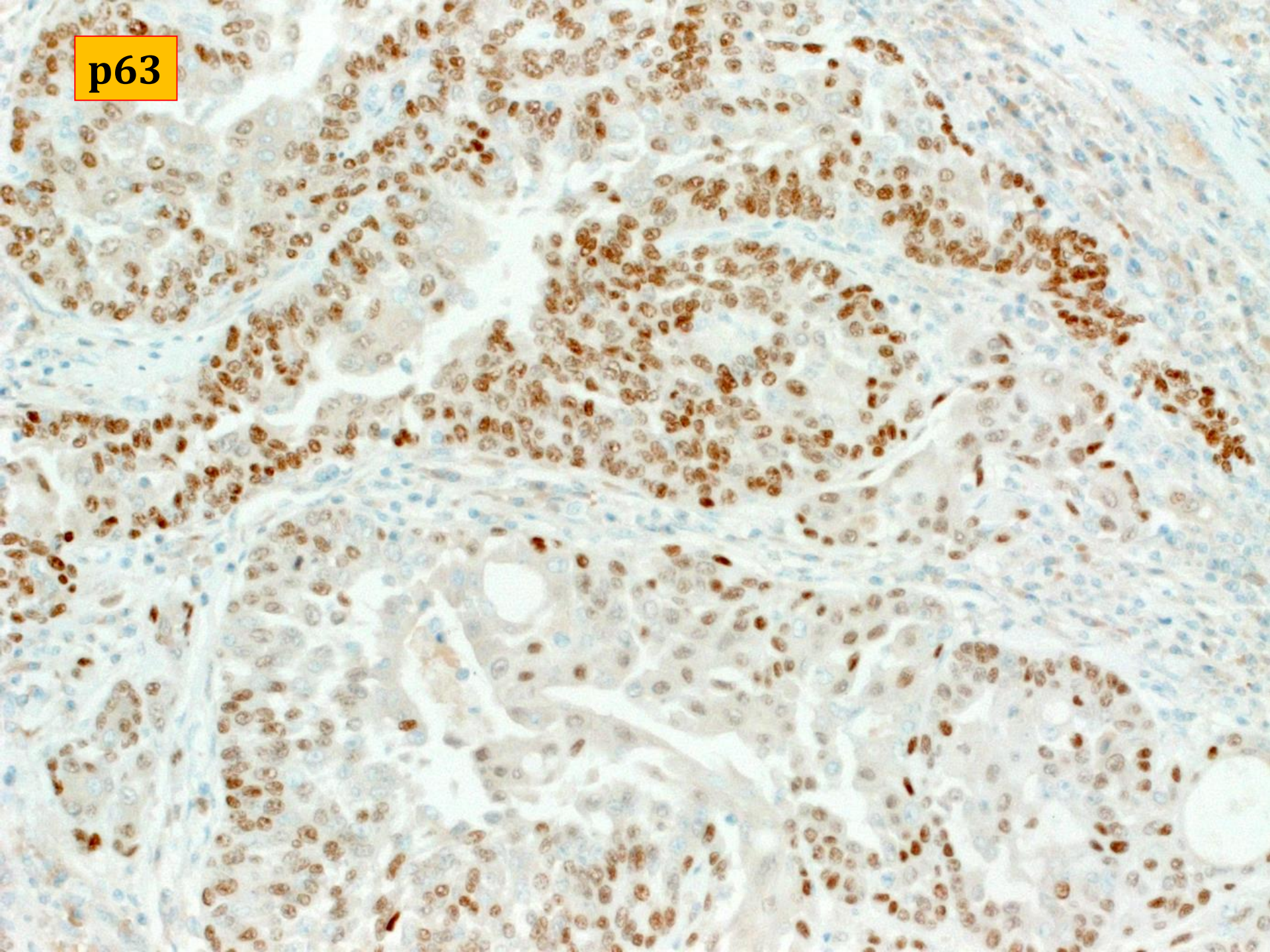






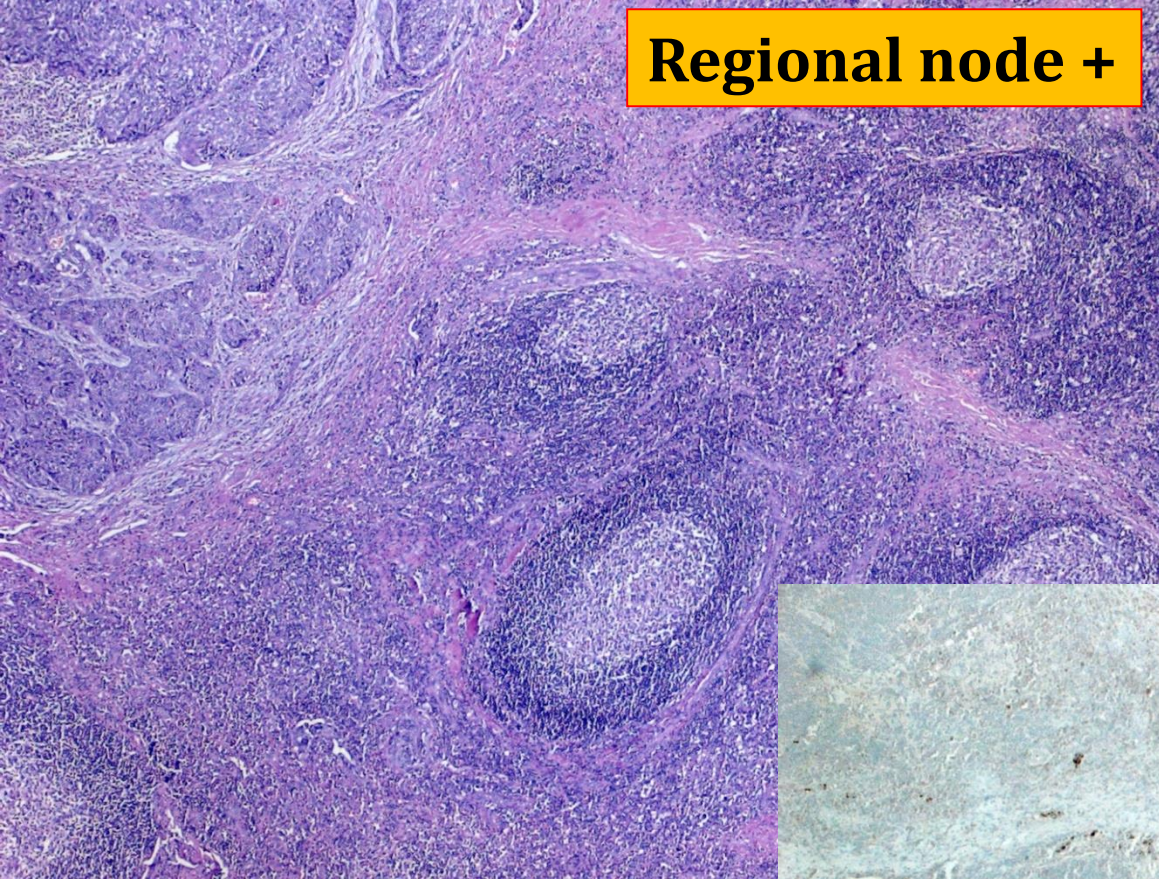


p63



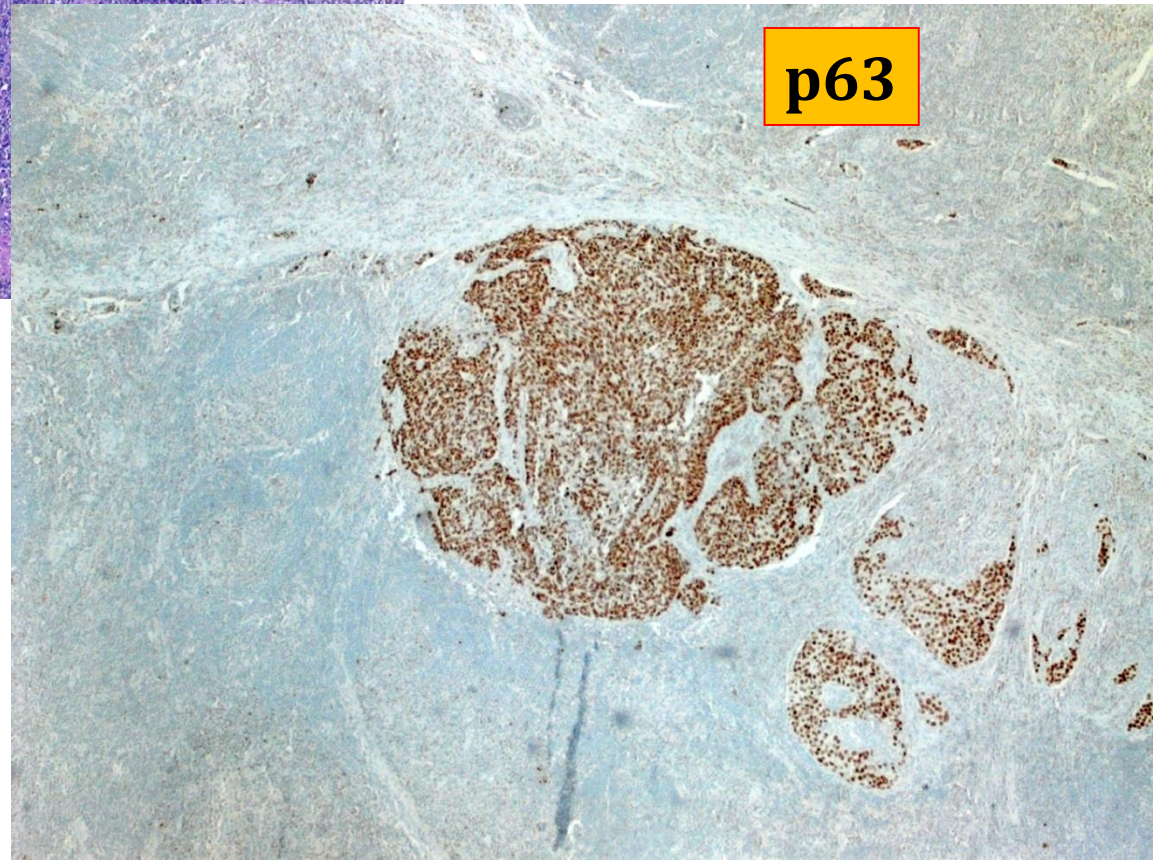


**Regional node +**



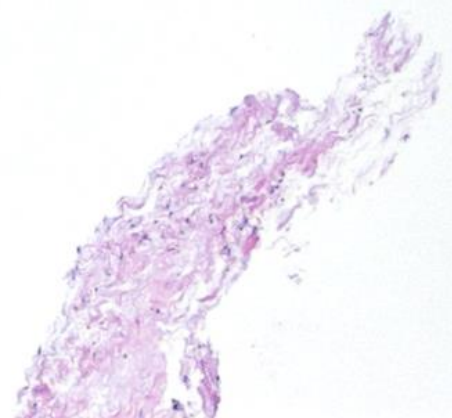
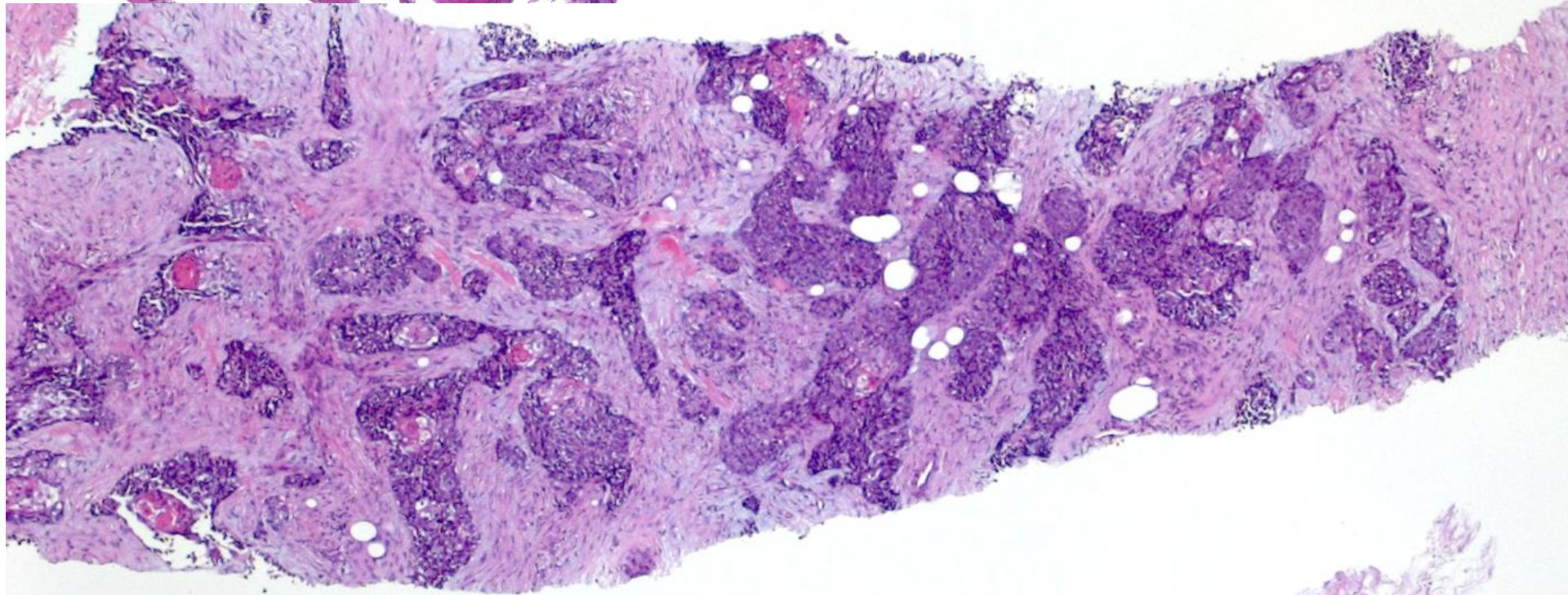
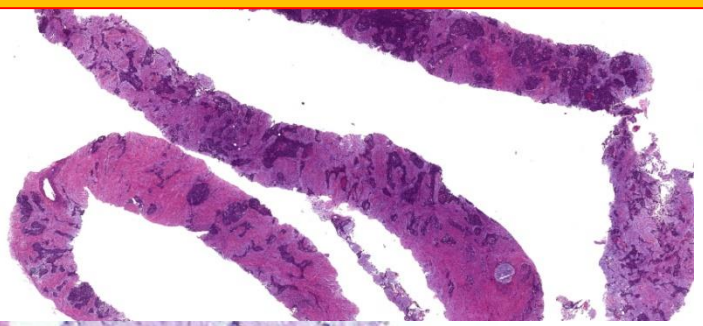
**Case diagnosed  
As sclerosing MEC  
with eosinophilia  
(SMECE)**

**p63**

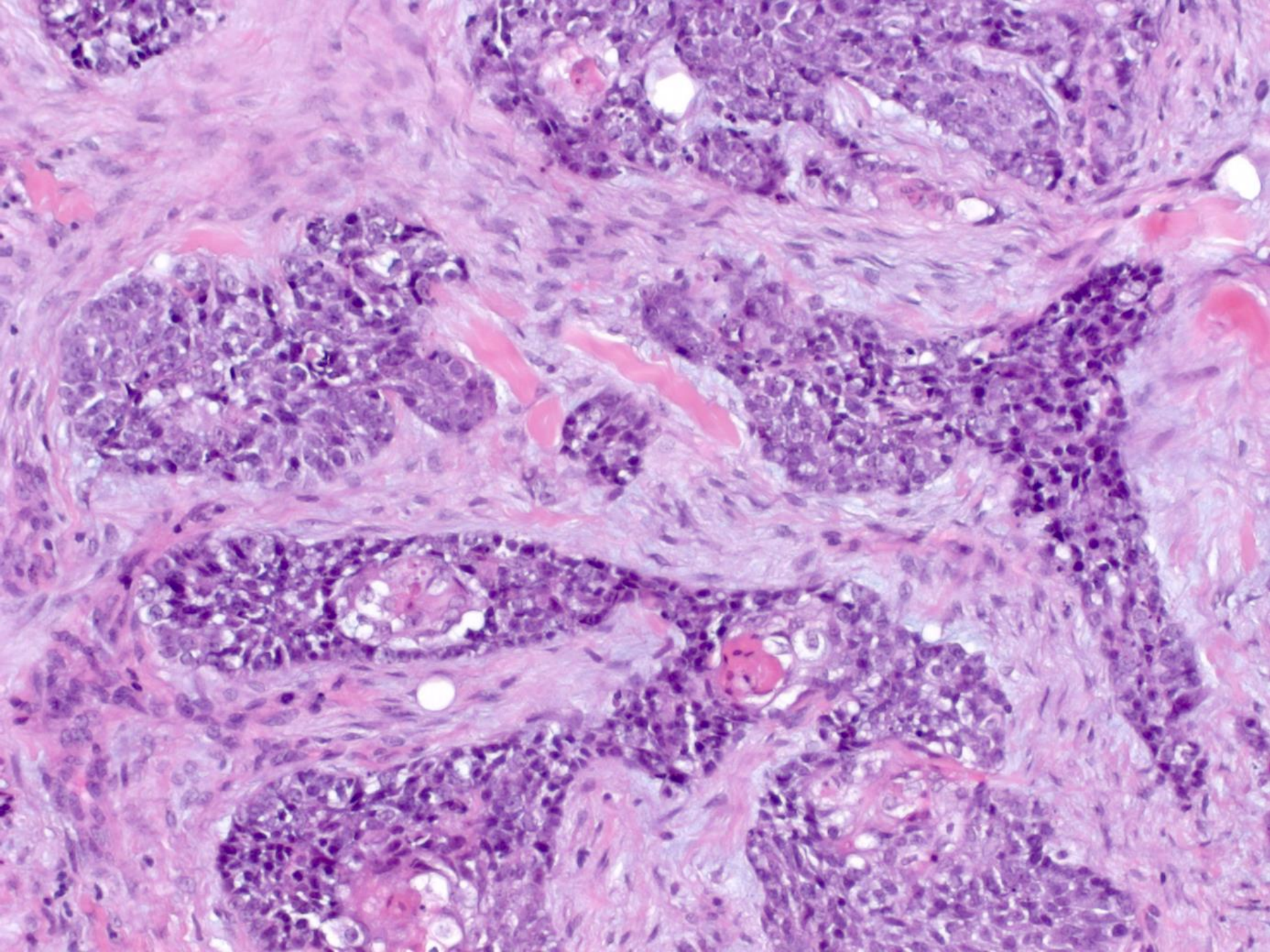




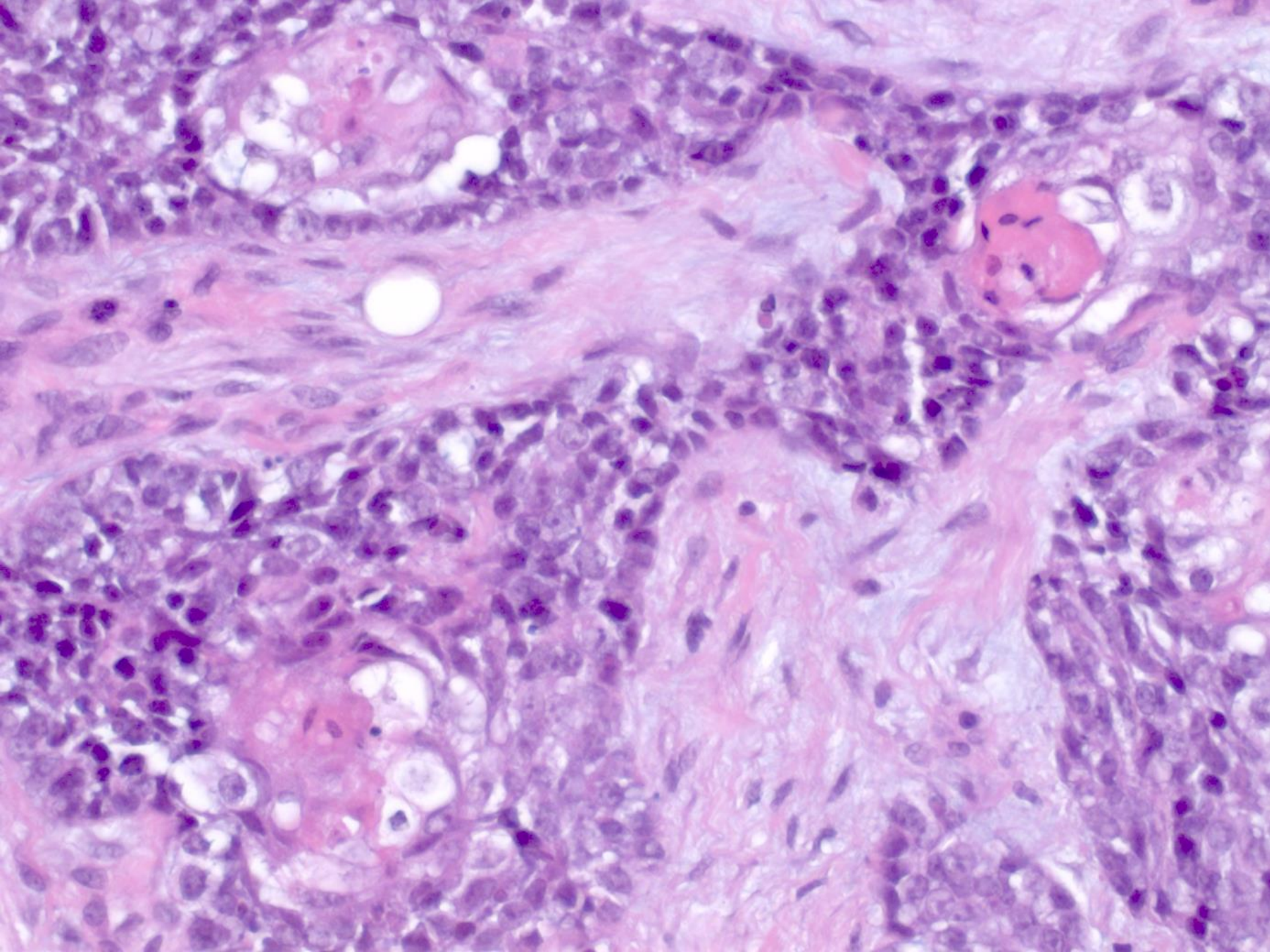
**6 mo later, extensive neck rec, tracheal infiltration, core biopsy**





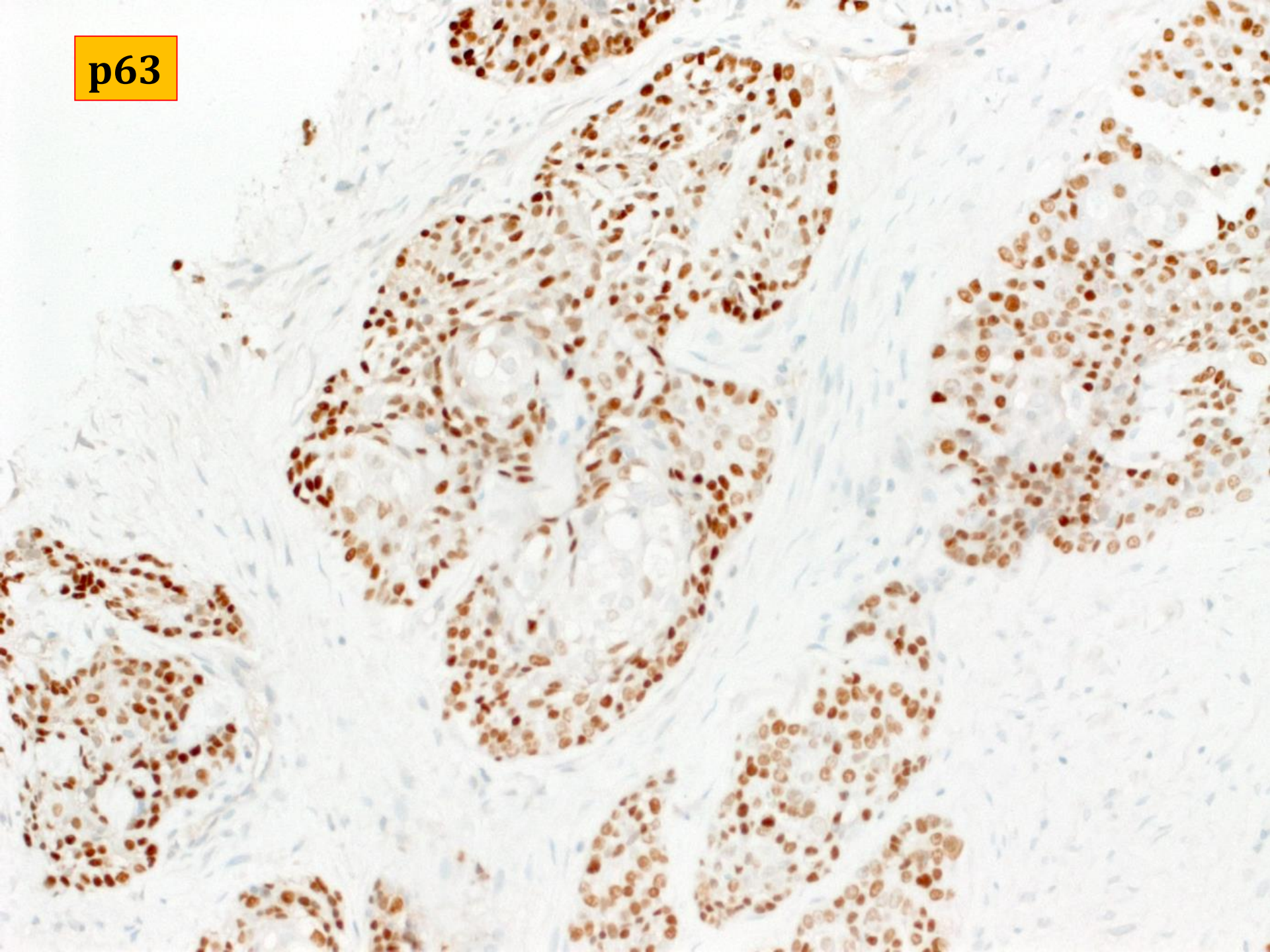






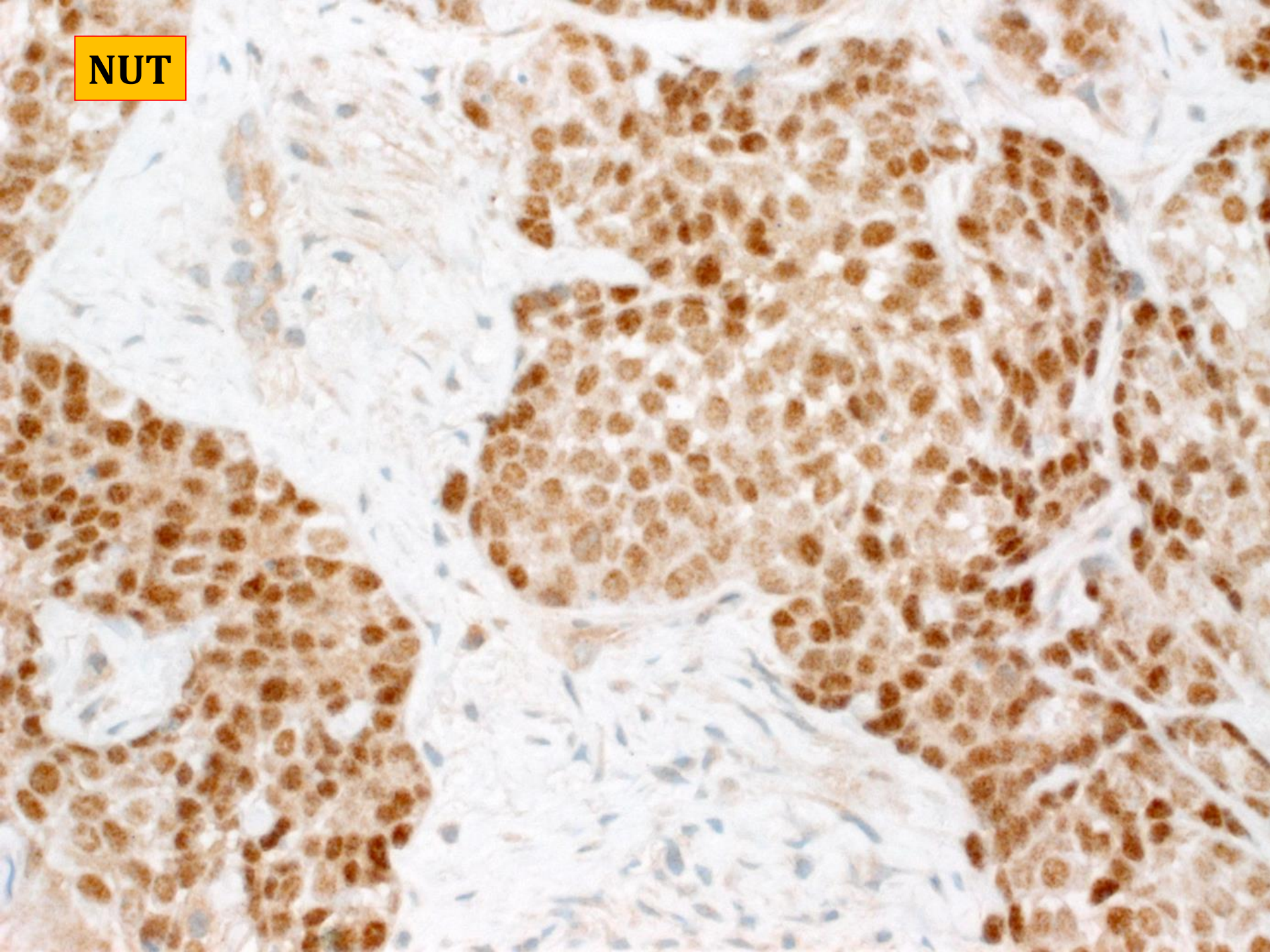


**p63**





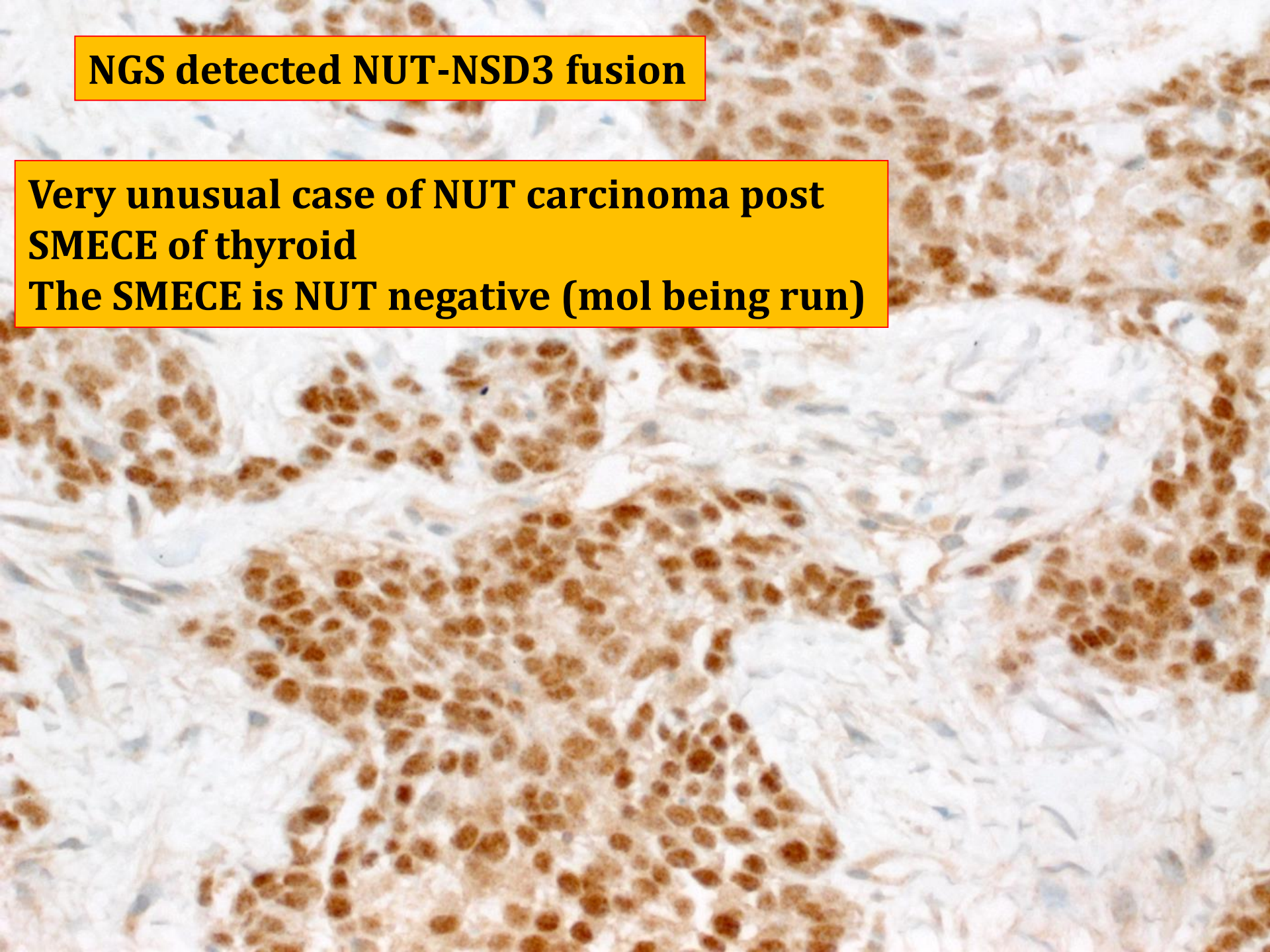
**NUT**





**NGS detected NUT-NSD3 fusion**

**Very unusual case of NUT carcinoma post  
SMECE of thyroid  
The SMECE is NUT negative (mol being run)**

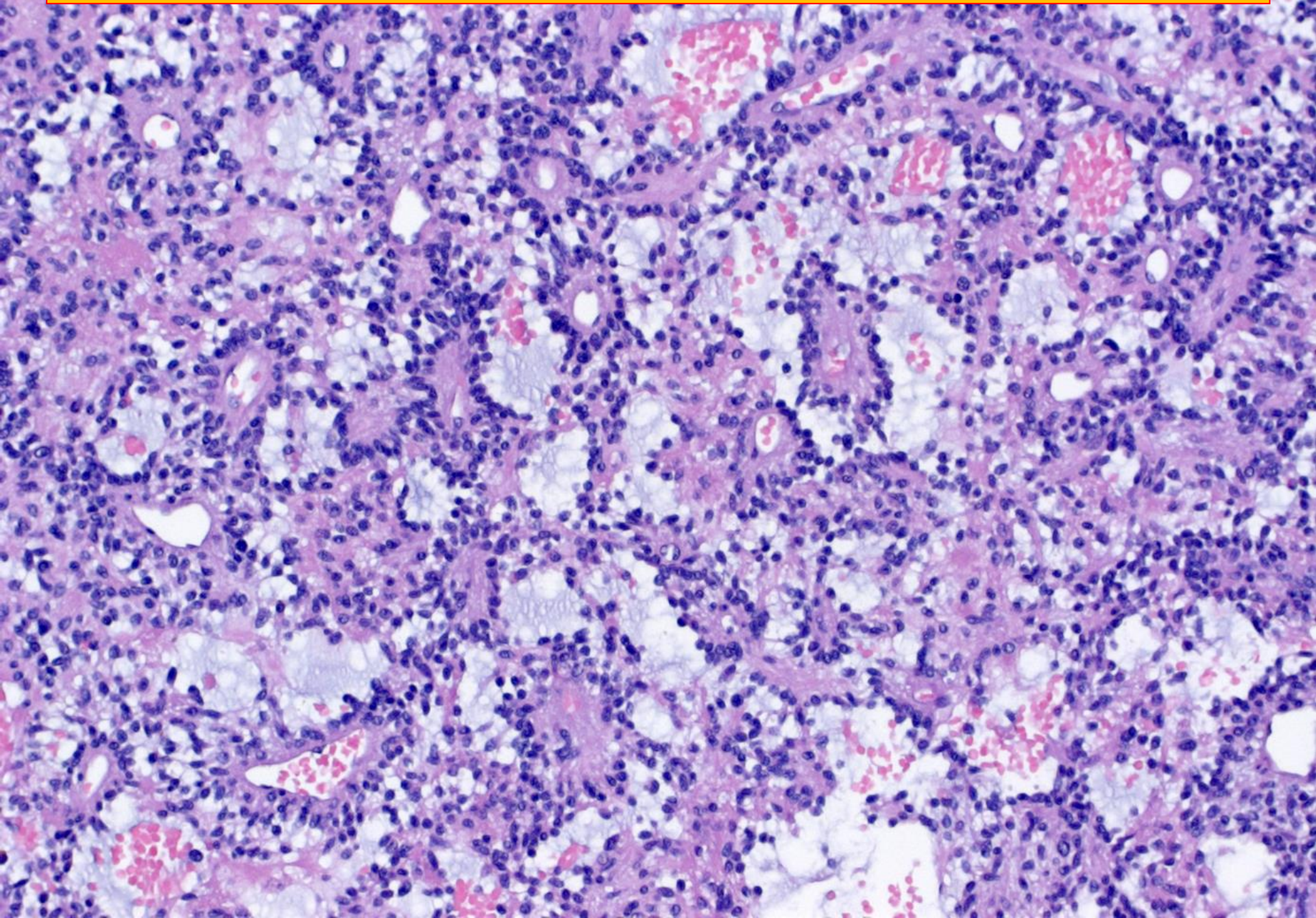




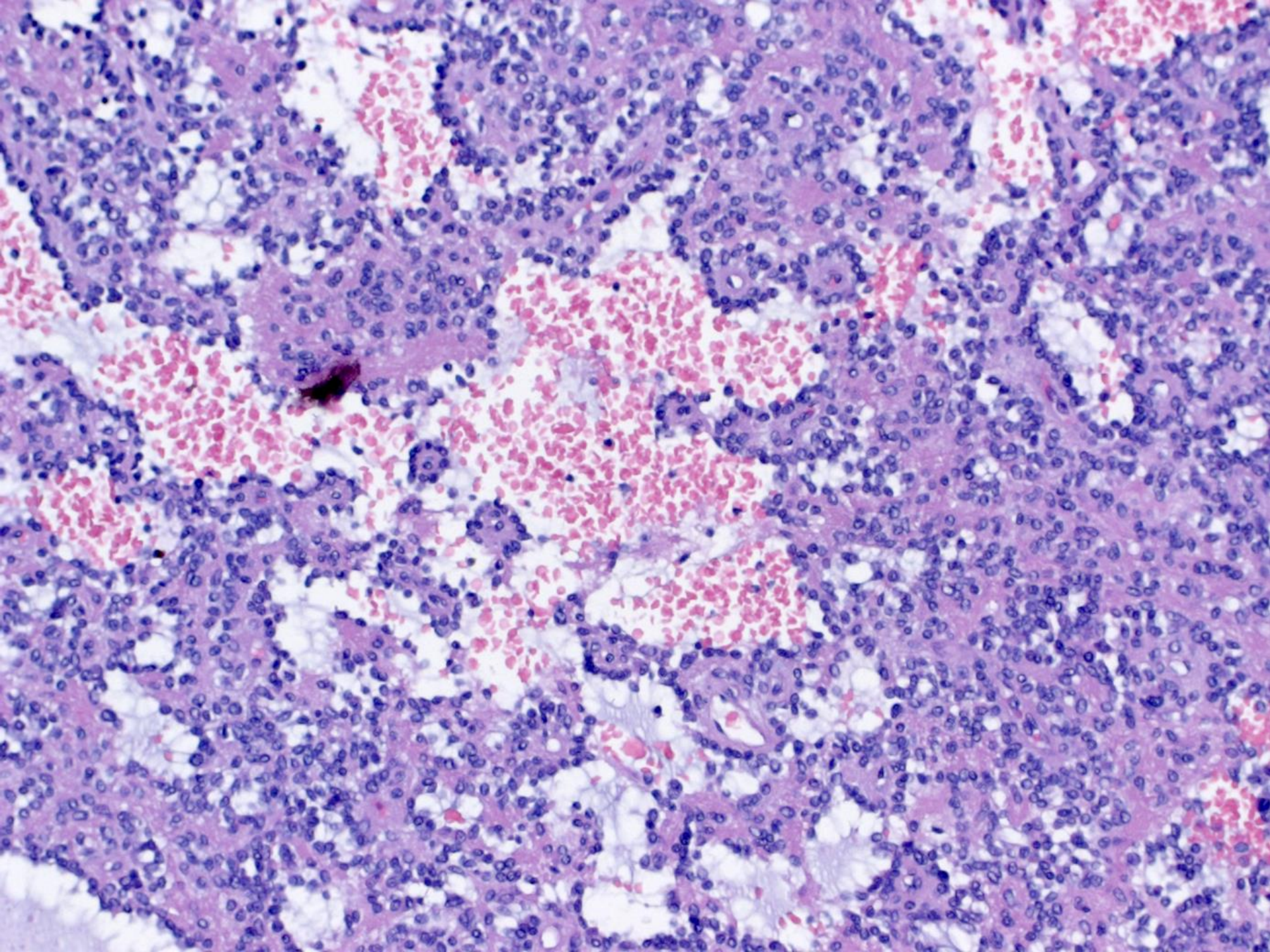




**72 yo male with temporal deep mass in soft tissue and bone**



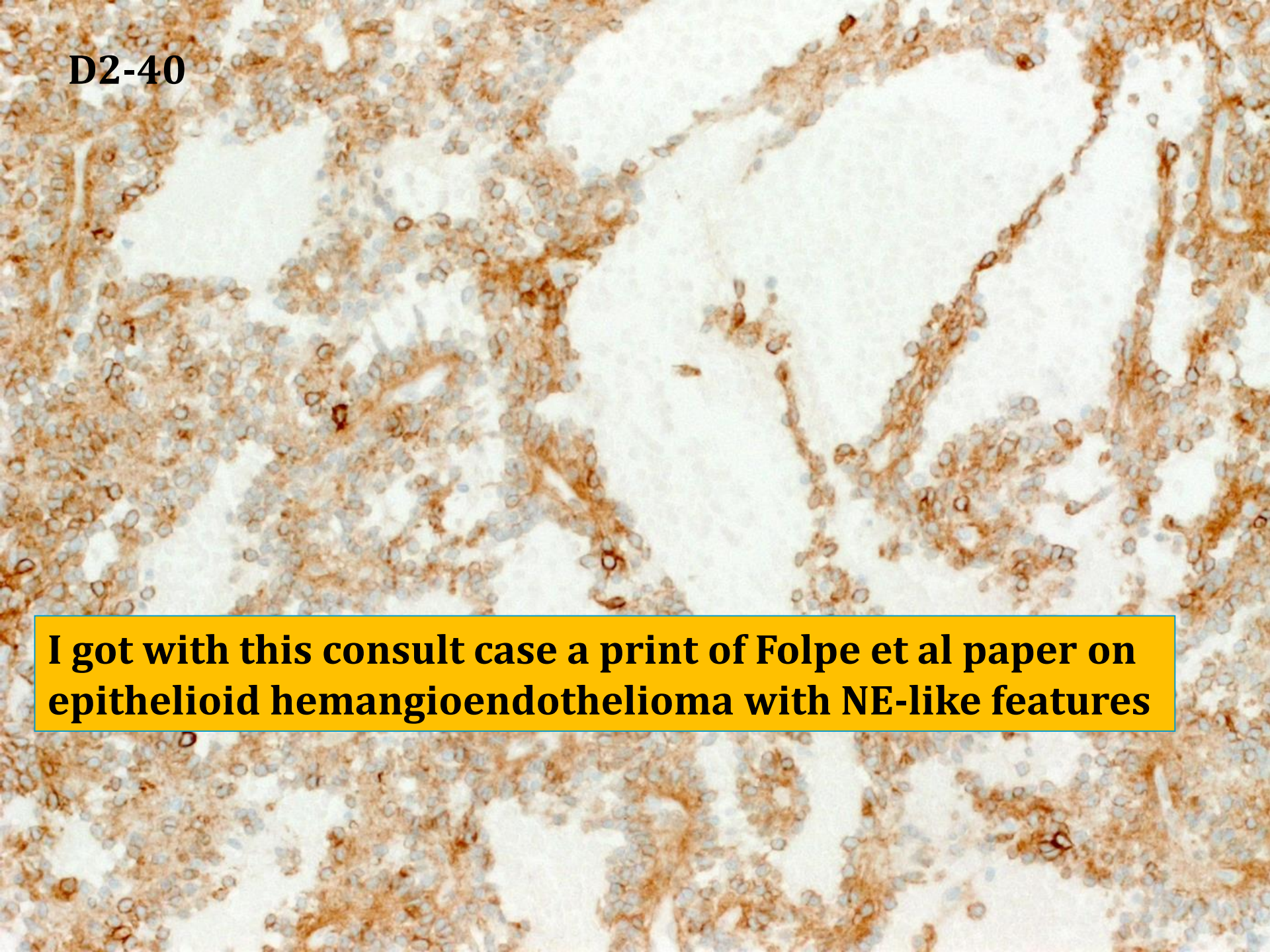






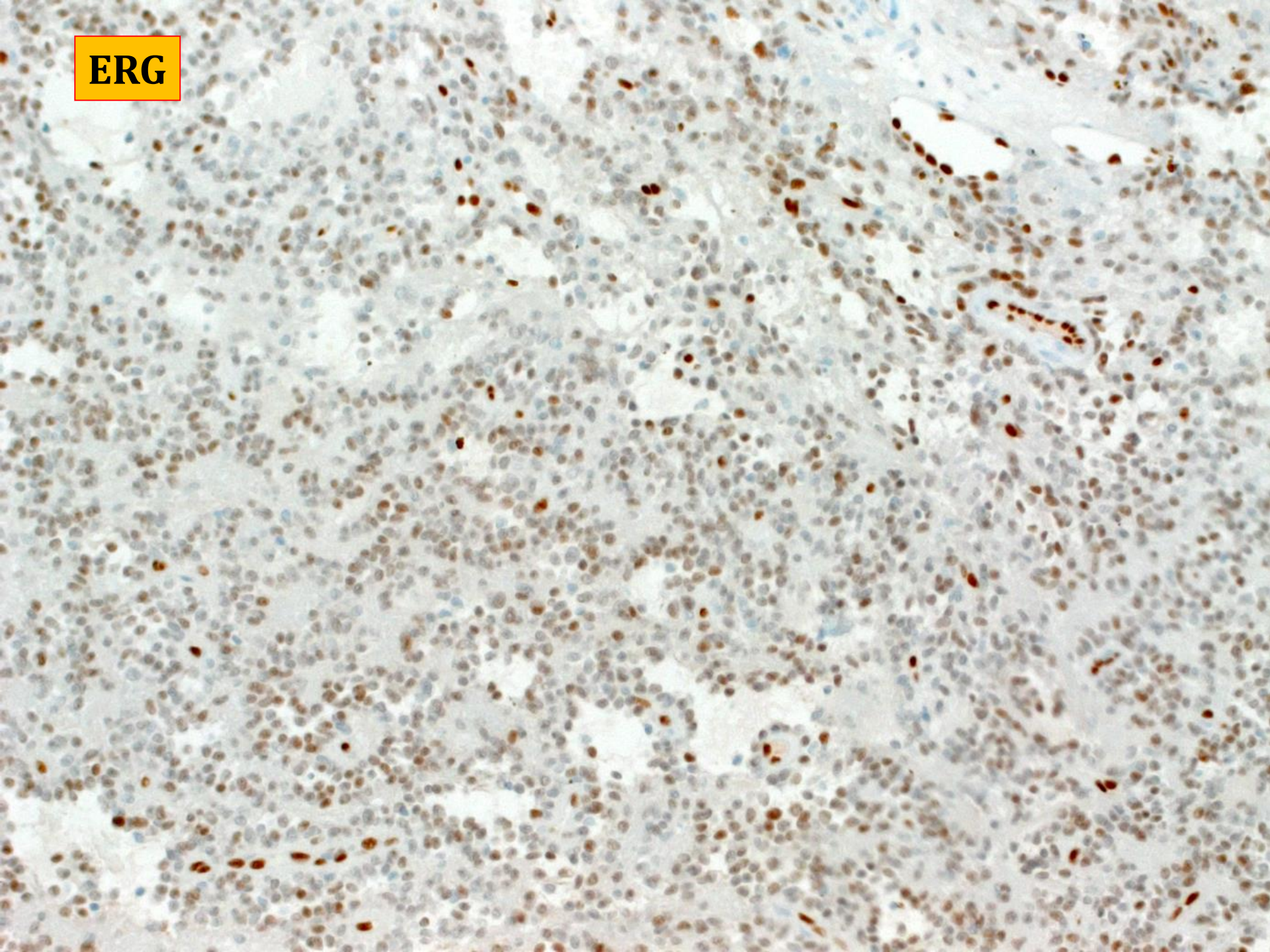
**D2-40**

**I got with this consult case a print of Folpe et al paper on epithelioid hemangioendothelioma with NE-like features**





**ERG**





Andrew L. Folpe, MD. Department of Laboratory Medicine and Pathology, Mayo Clinic,  
Rochester, MN, USA 55905

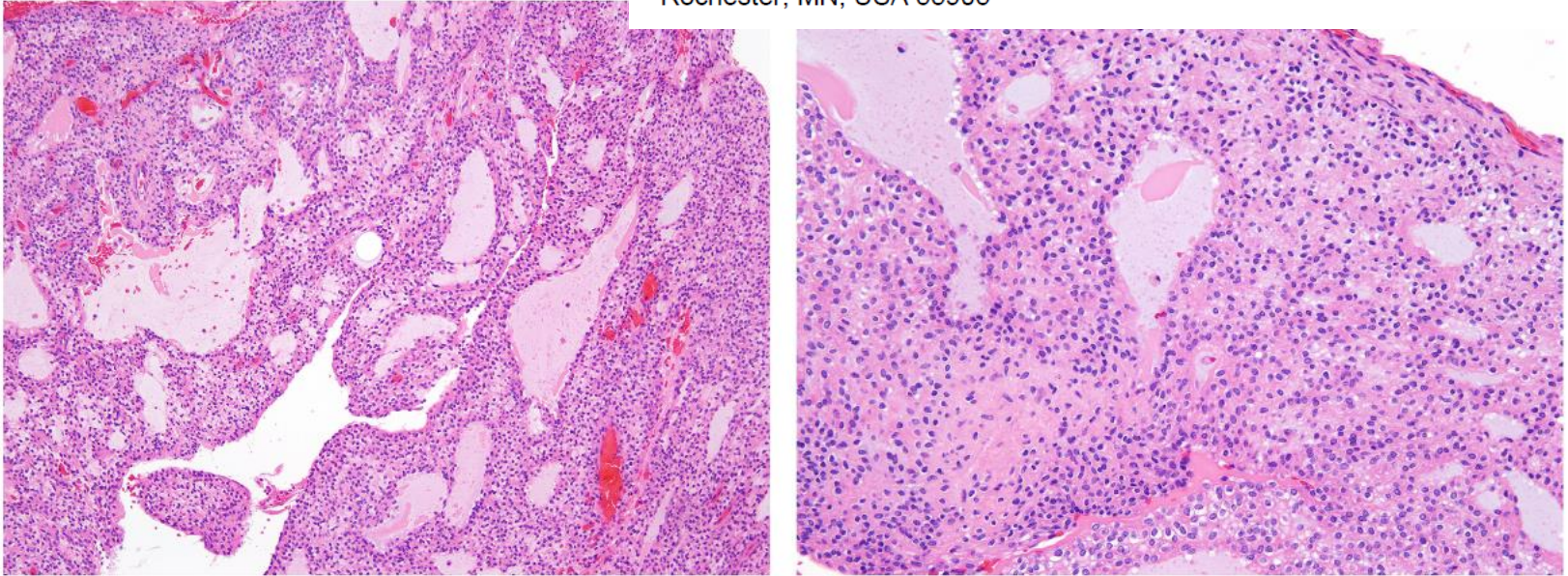


Figure 4: Phosphaturic mesenchymal tumor from the cerebellopontine angle of a 35-year-old woman, clinically mimicking schwannoma. This tumor nicely illustrates a less well-known morphologic pattern of these tumors, consisting of a vaguely endocrine-appearing, trabecular proliferation of round to epithelioid cells in a microcystic, partially myxoid background (A). At higher power magnification, such tumors often contain small

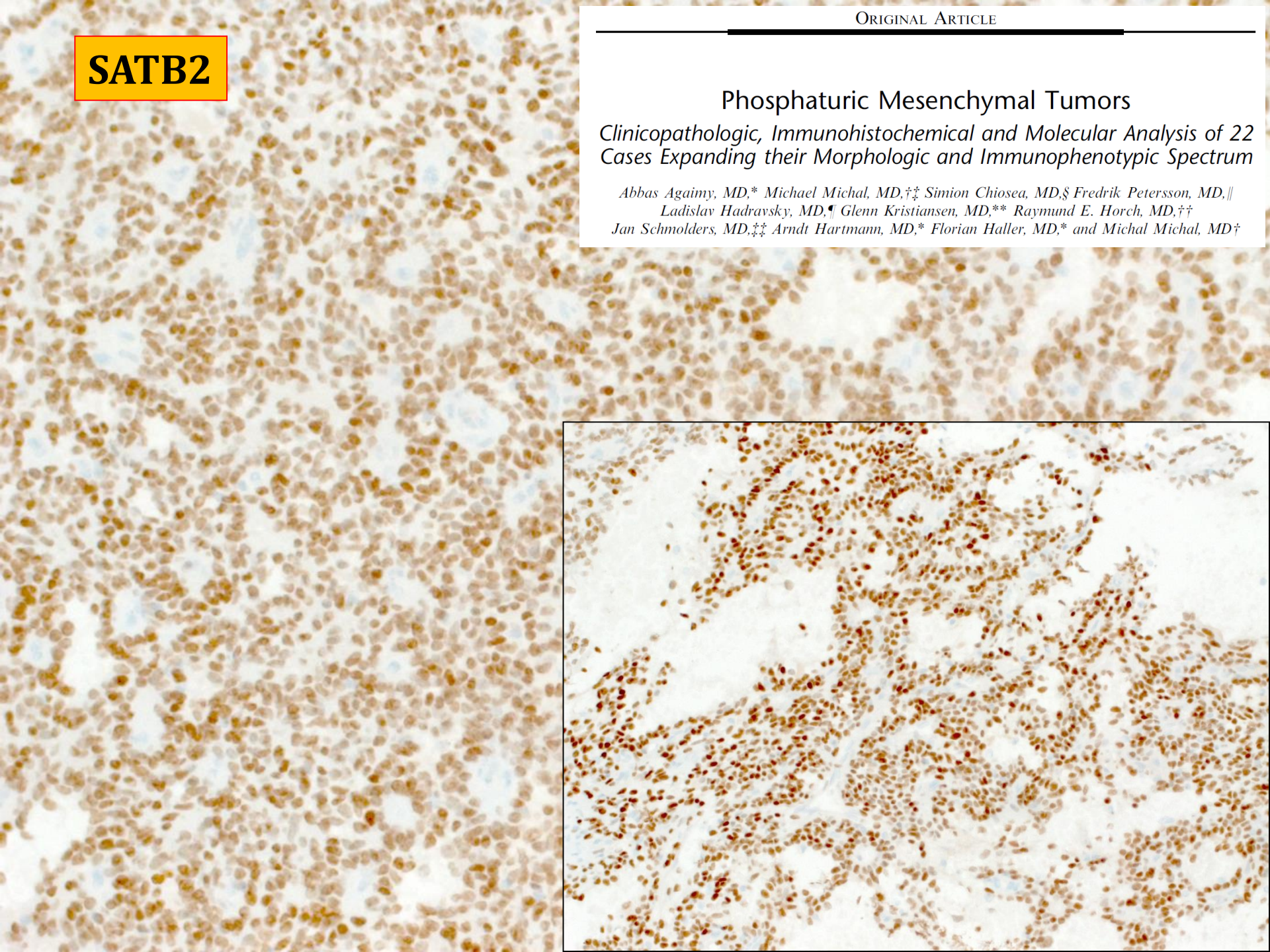


**SATB2**

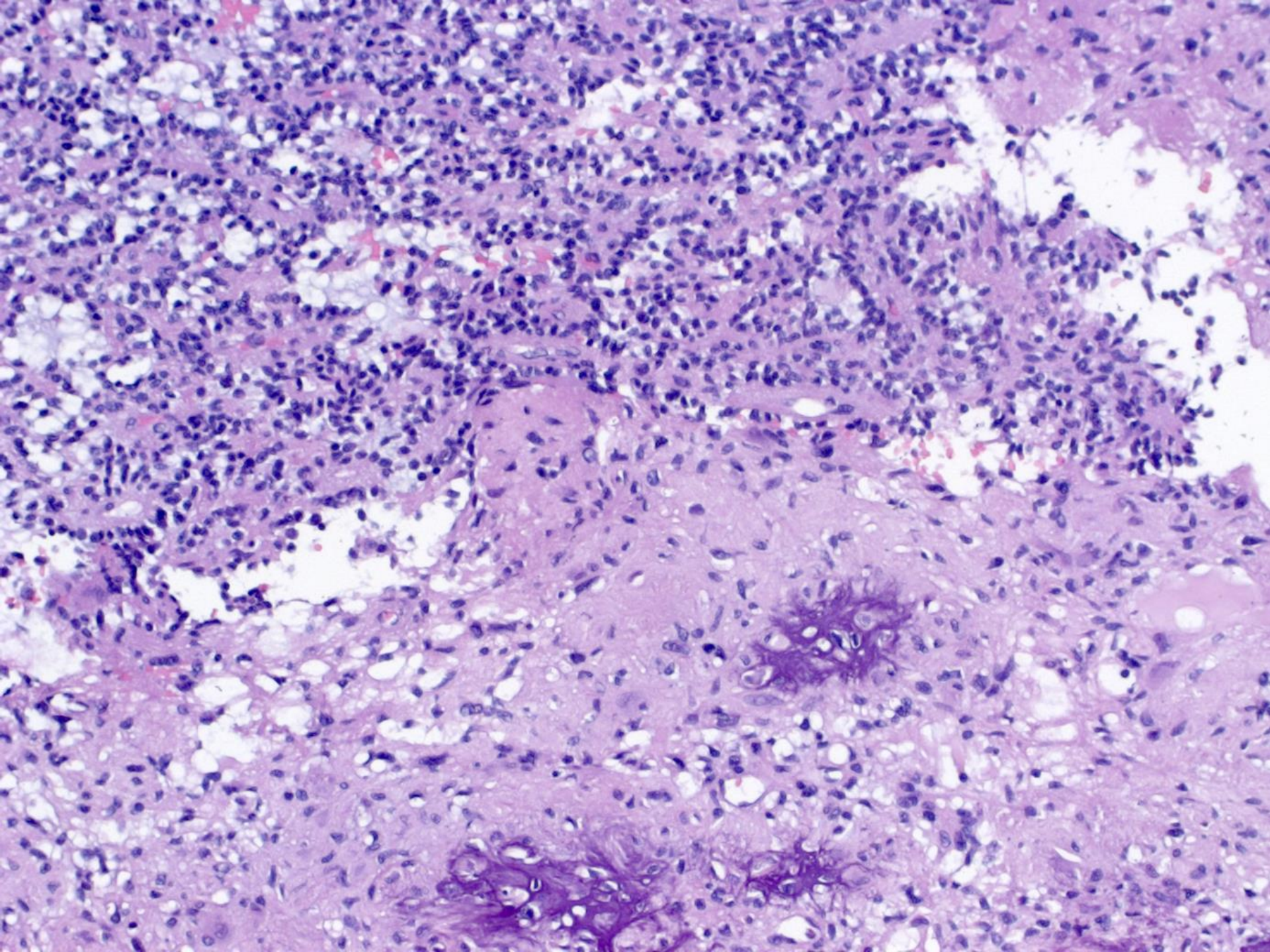
## Phosphaturic Mesenchymal Tumors

*Clinicopathologic, Immunohistochemical and Molecular Analysis of 22 Cases Expanding their Morphologic and Immunophenotypic Spectrum*

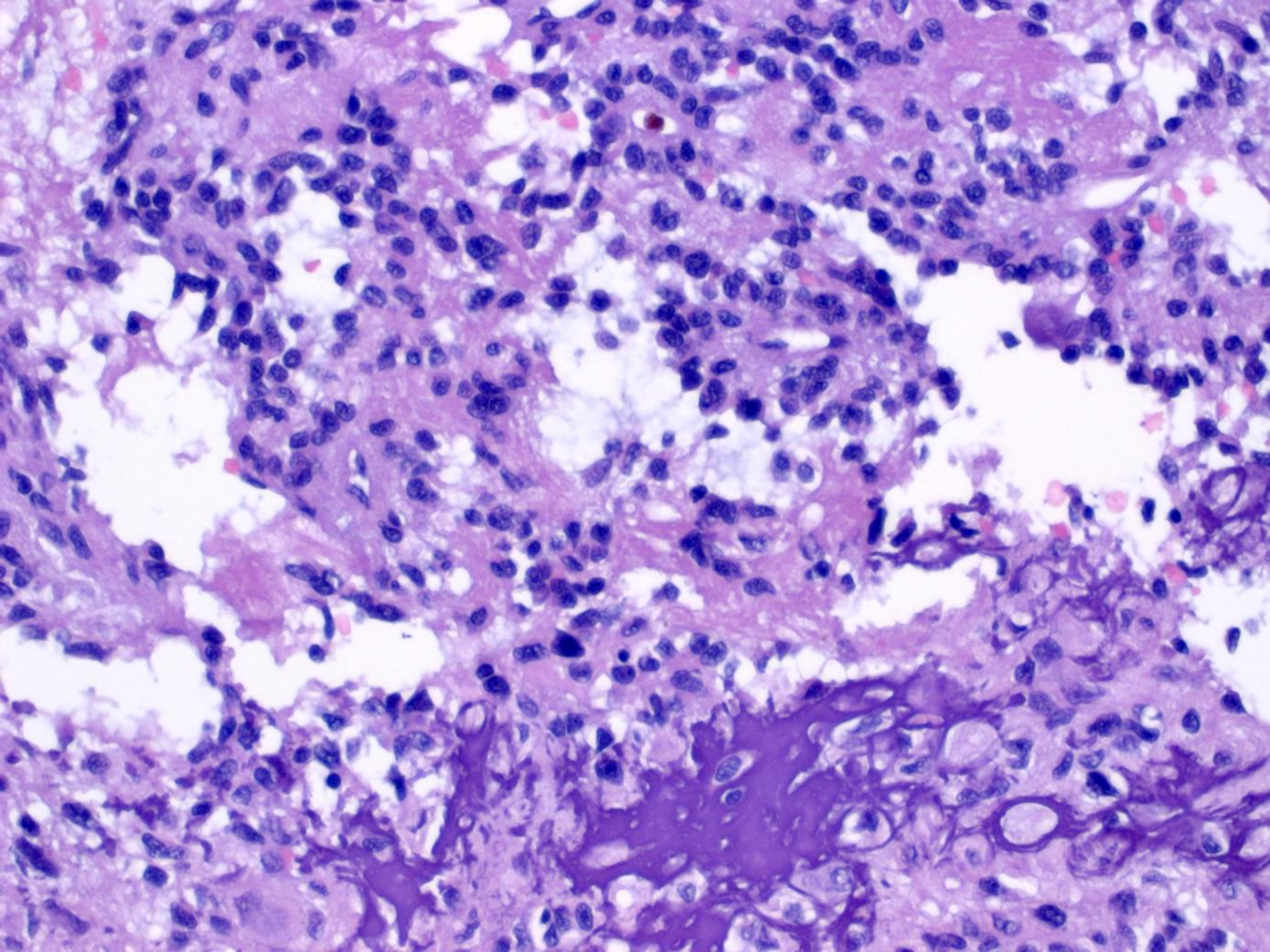
*Abbas Agaimy, MD,\* Michael Michal, MD,†‡ Simion Chiosea, MD,§ Fredrik Petersson, MD,||  
Ladislav Hadravsky, MD,¶ Glenn Kristiansen, MD,\*\* Raymund E. Horch, MD,††  
Jan Schmolders, MD,‡‡ Arndt Hartmann, MD,\* Florian Haller, MD,\* and Michal Michal, MD†*













**Do not put the cart (IHC) in front of the horse (HE)**

